


Skin in the Game: An Obstetrician's Guide to Dermatology

Eric H. Dellinger, MD
USCSOM-Greenville
Greenville, SC



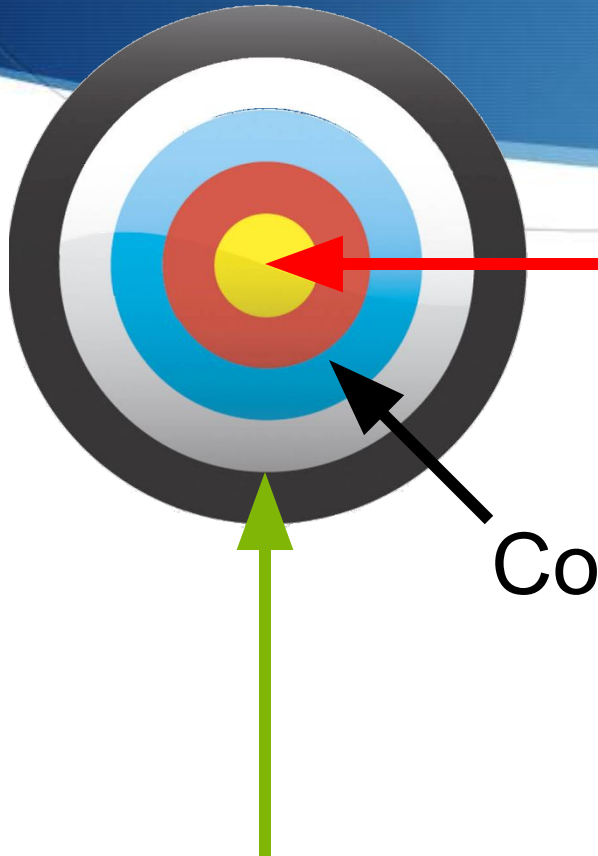
Artist: Kehinde Wiley



Dermatology Made Easy

- 💧 Repetition
- 💧 If it's dry, wet it
- 💧 If it's wet, dry it
- 💧 Apply topical steroids
- 💧 Rx oral steroids
- 💧 If at all possible, perform an excisional biopsy

Goals



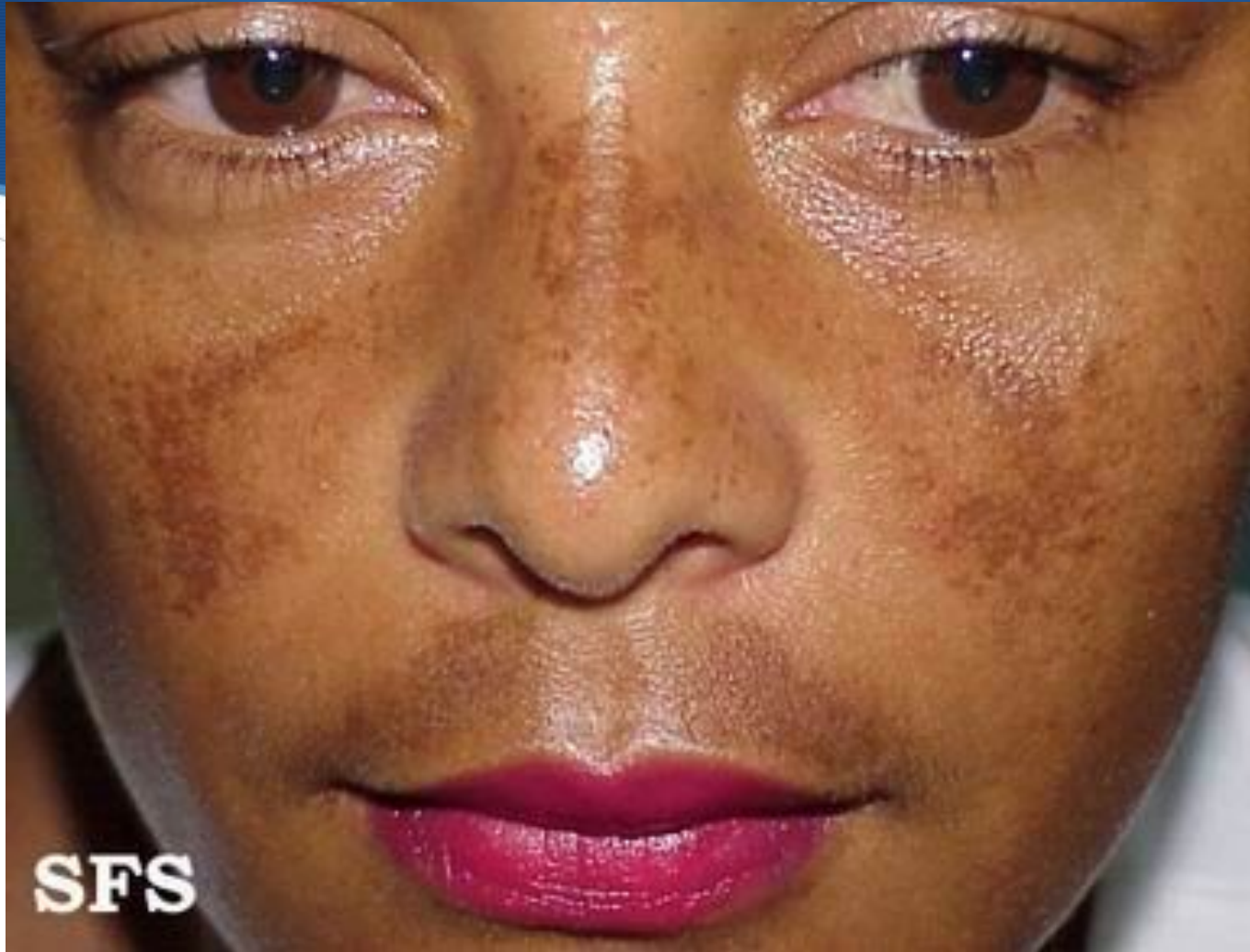Dermatology of pregnancy effects

Conditions affecting pregnancy

Conditions in Obstetrics and Gynecology

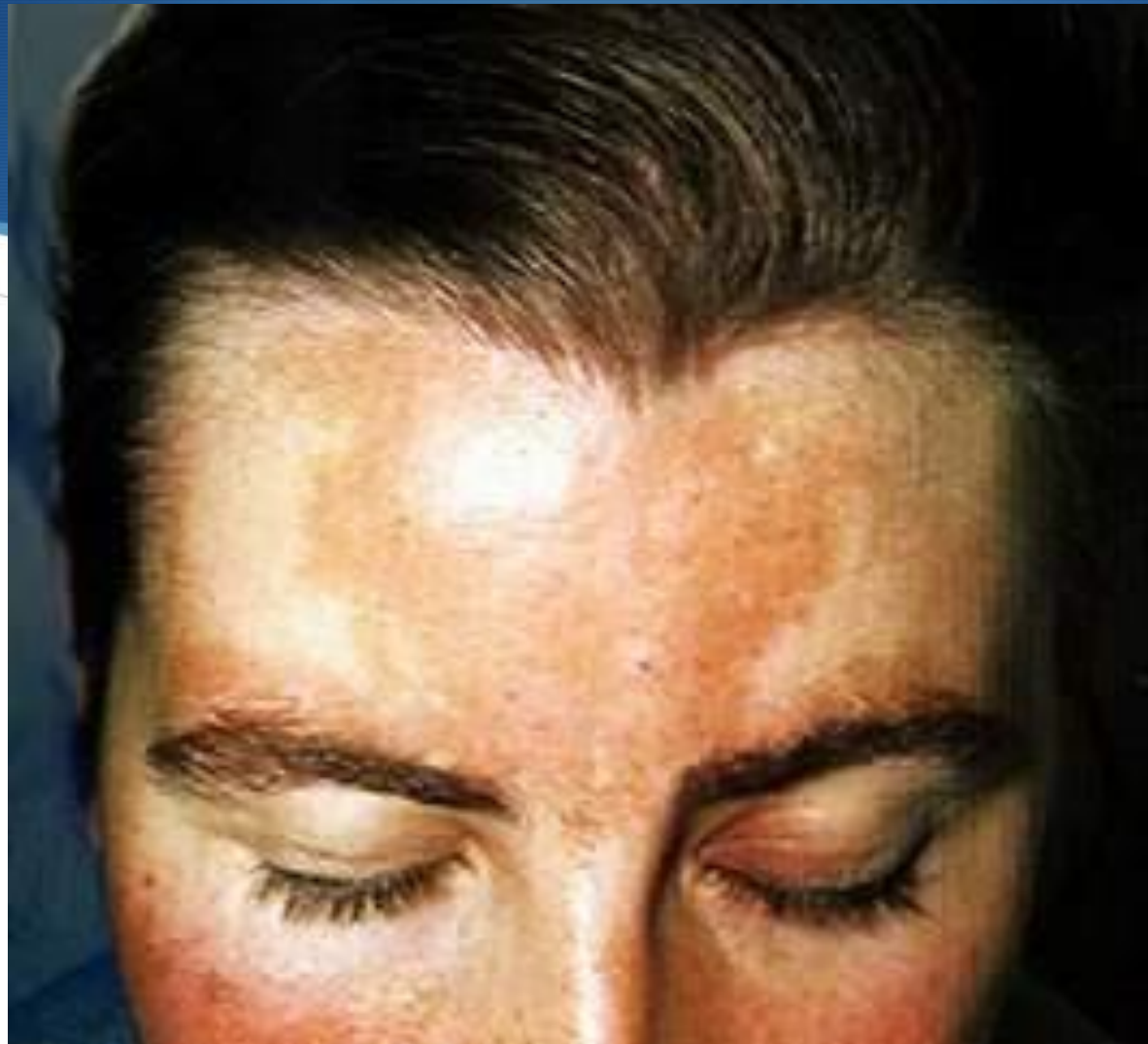Pregnancy: Skin Changes



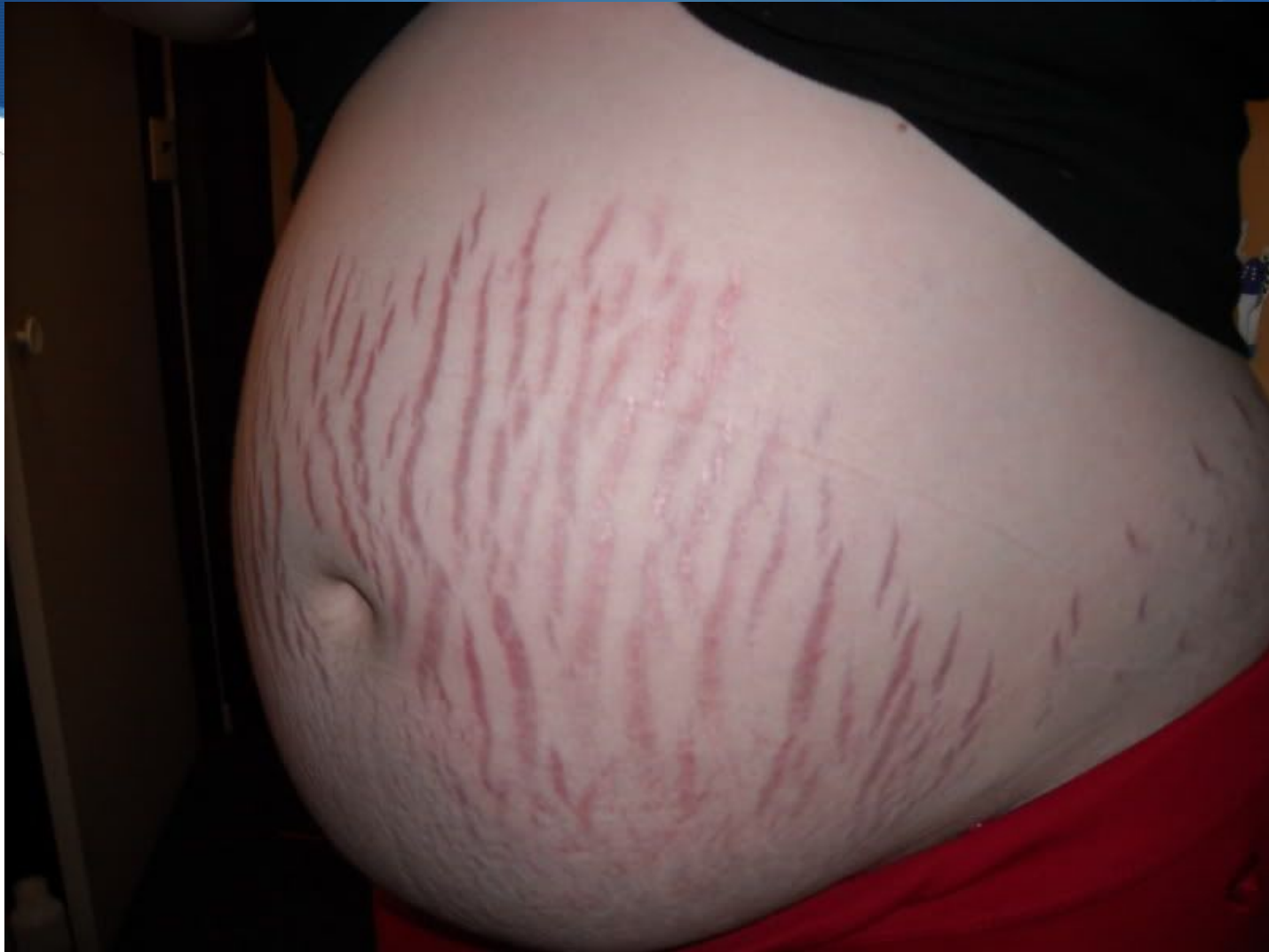

Melasma

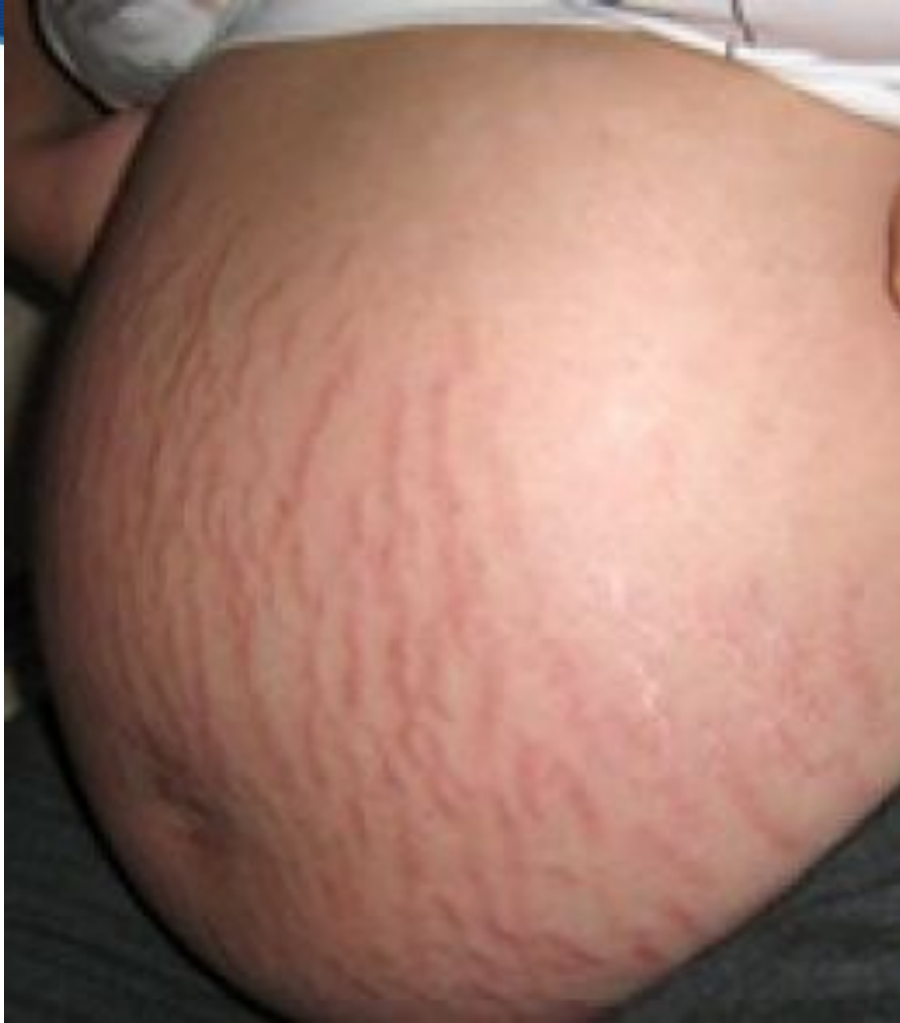- 💧 Mask of pregnancy
- 💧 Common in pregnant women, women taking OCPs, and women taking HRT
- 💧 Tretinoin cream containing hydroquinone may be helpful in fading some types of melasma
- 💧 Chemical peels or topical steroid creams useful
- 💧 In severe cases, laser treatments can be used
- 💧 Sun avoidance and daily sunscreen use are key to avoiding melasma



Striae Gravidarum



Striae Gravidarum



60% develop SG.

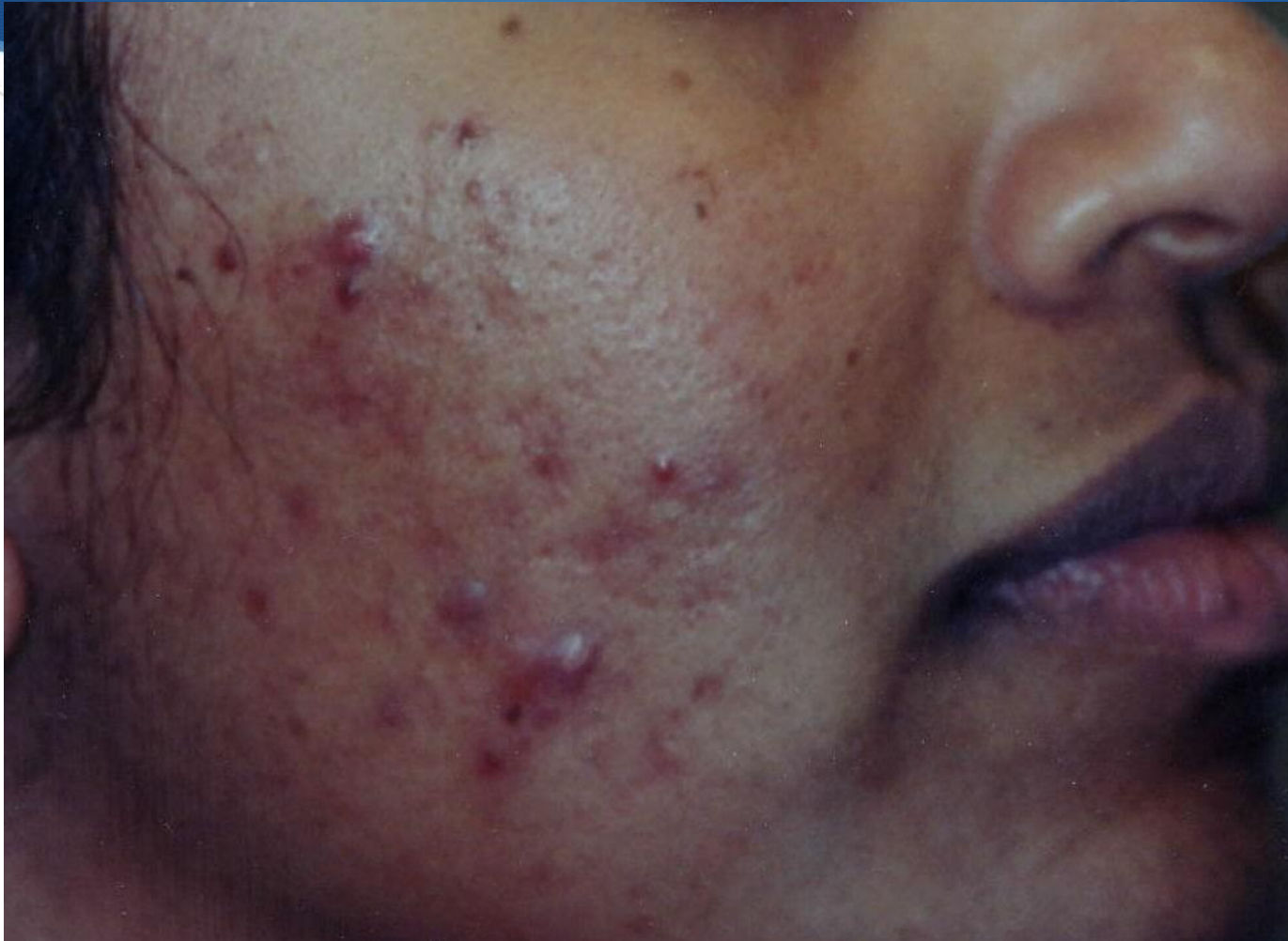Women who develop SG are younger (26.5 vs 30.5; $P < .001$).

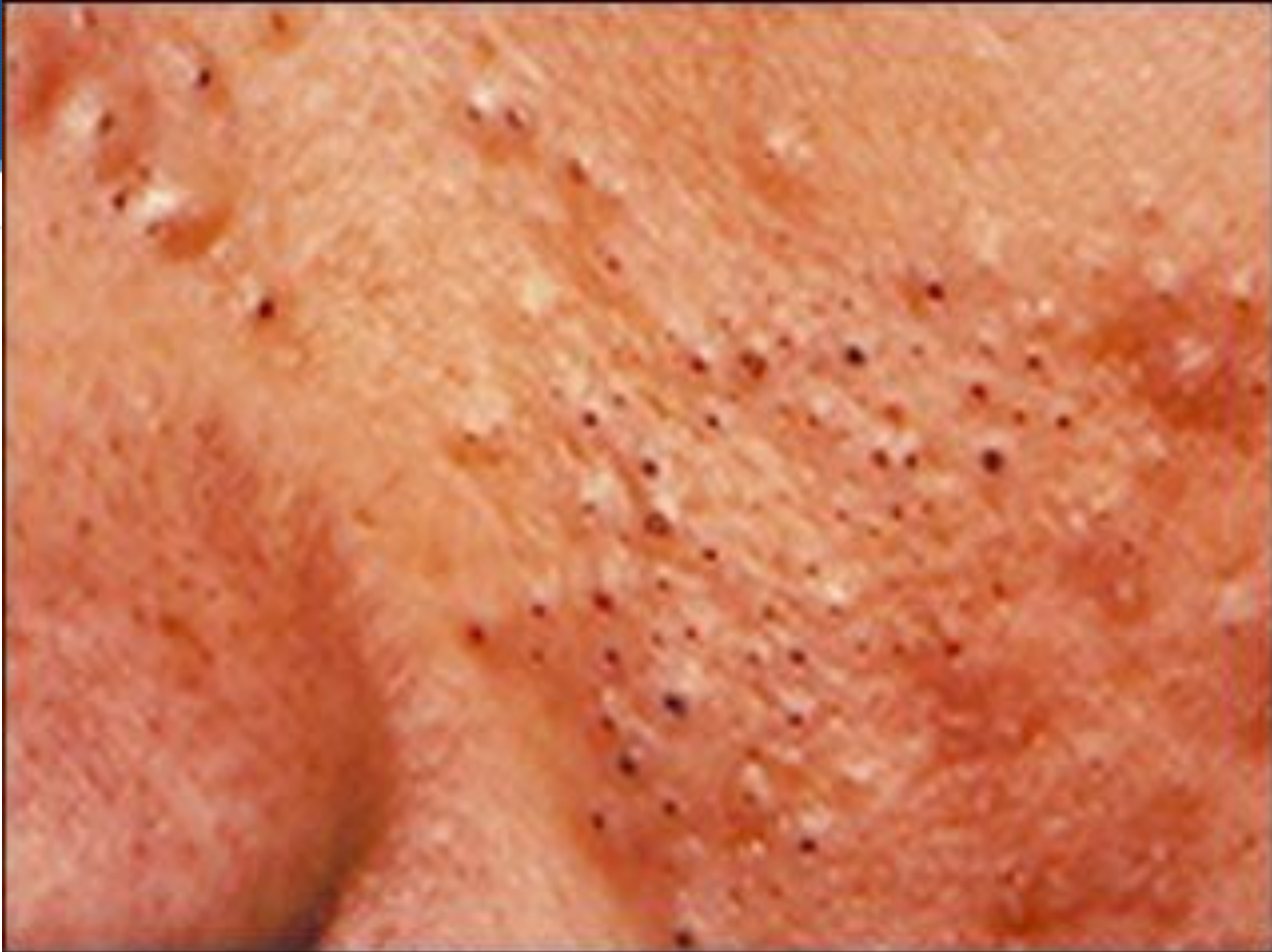They gain significantly more weight during pregnancy (15.6 vs 38.4 kg; $P < .001$).

No effective treatment.

Am J Obstet Gynecol. 2007 January; 196(1).

Acne







AC CUTANE[®] (isotretinoin)

40 mg

PRESCRIPTION
PAK

Each capsule contains
40 mg isotretinoin.



R_x only.

10 Capsules

**PATIENT:
READ INFORMATION
CAREFULLY.**

PEEL & SEAL

40 mg

PHARMACISTS: DIS
THIS AREA FOR PRES

WARNING TO FEMALE PATIENTS
AC CUTANE[®] MAY CAUSE SEVERE BIRTH DEFECTS.

PUSH THRU HERE

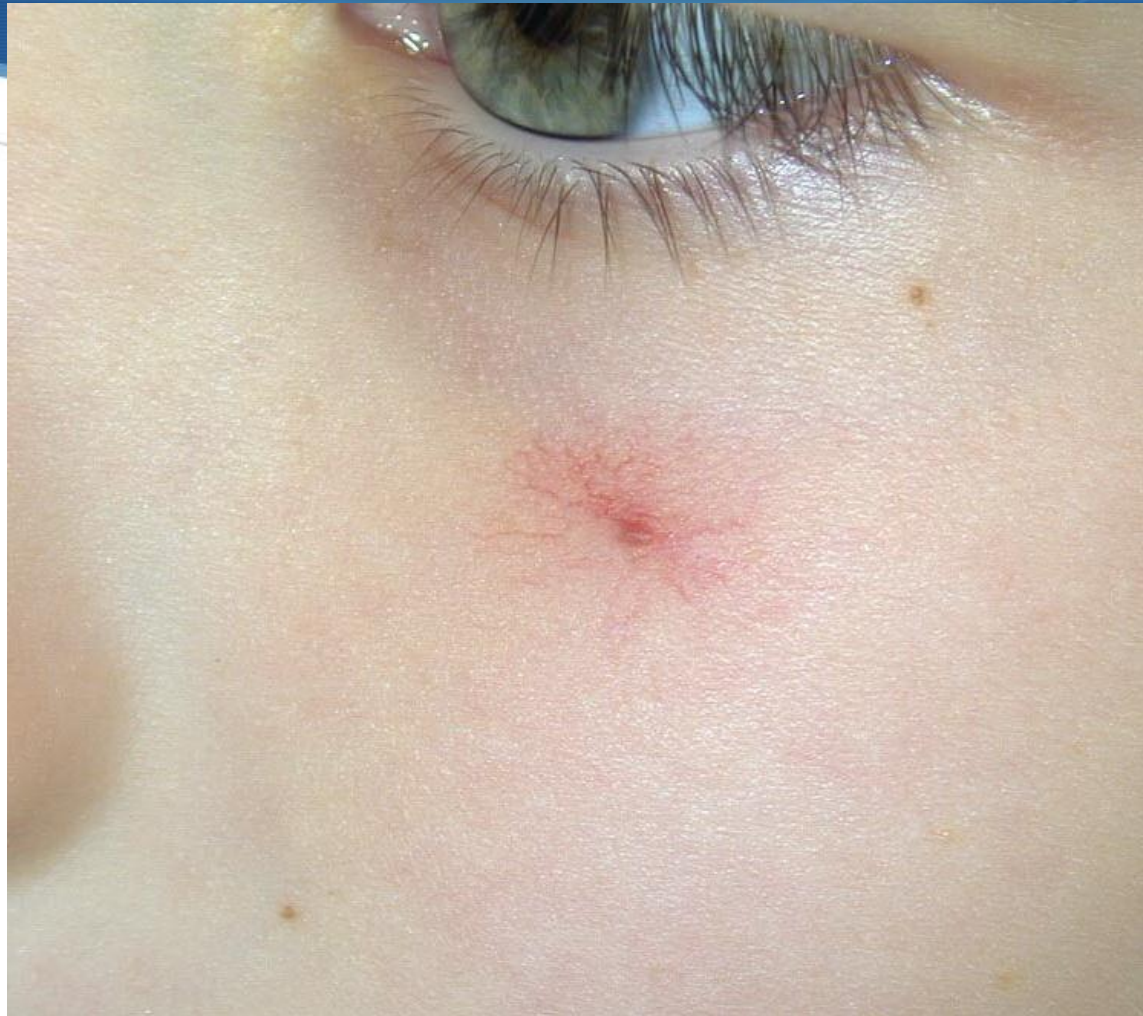WARNING TO FEMALE PATIENTS AVOID PREGNANCY

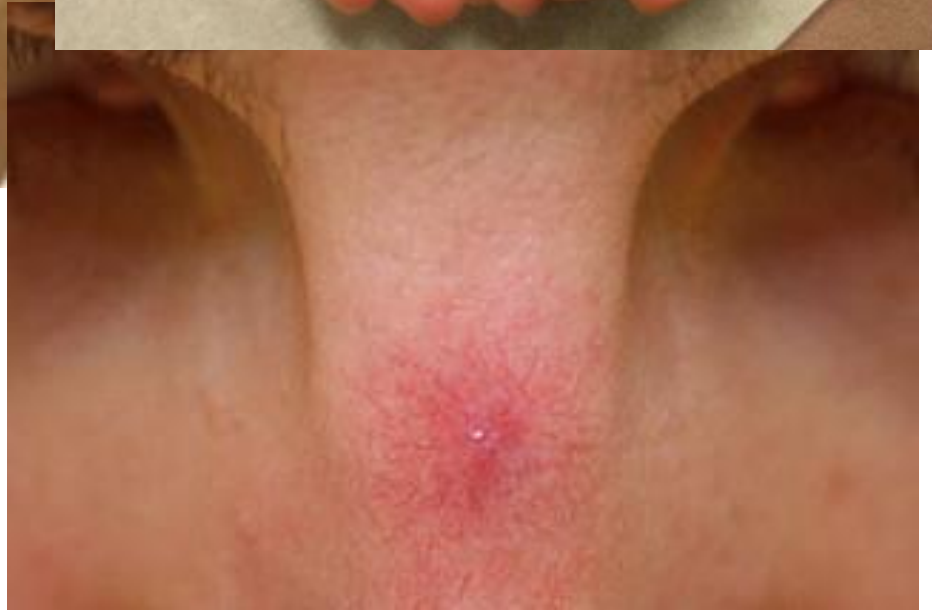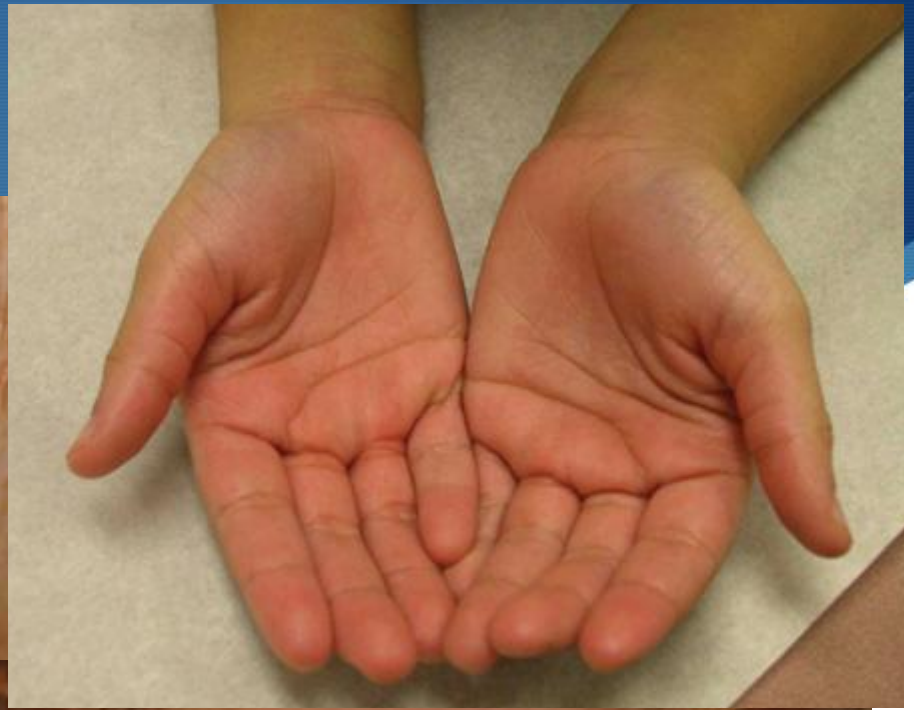
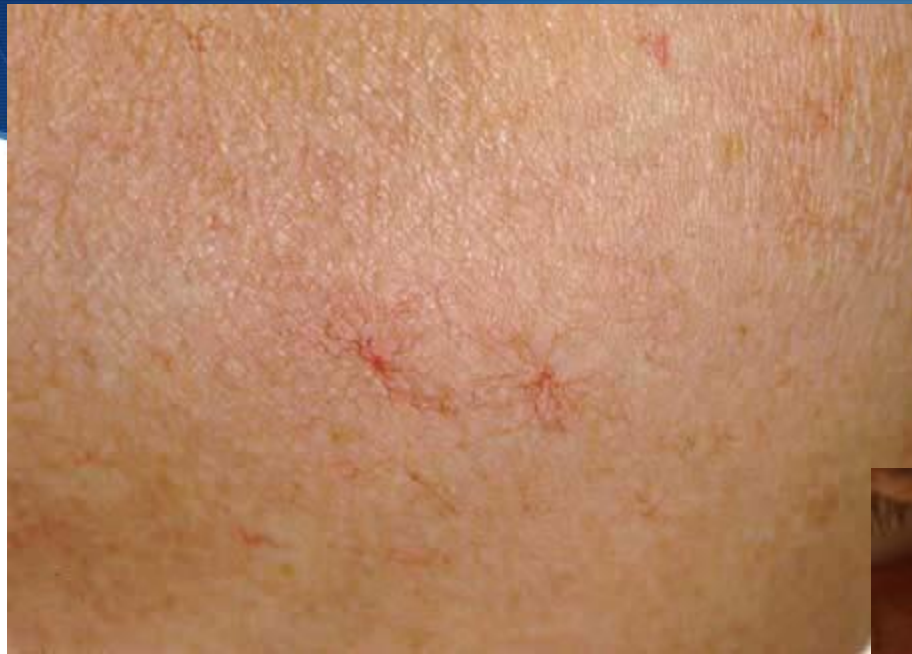PUSH THRU HERE

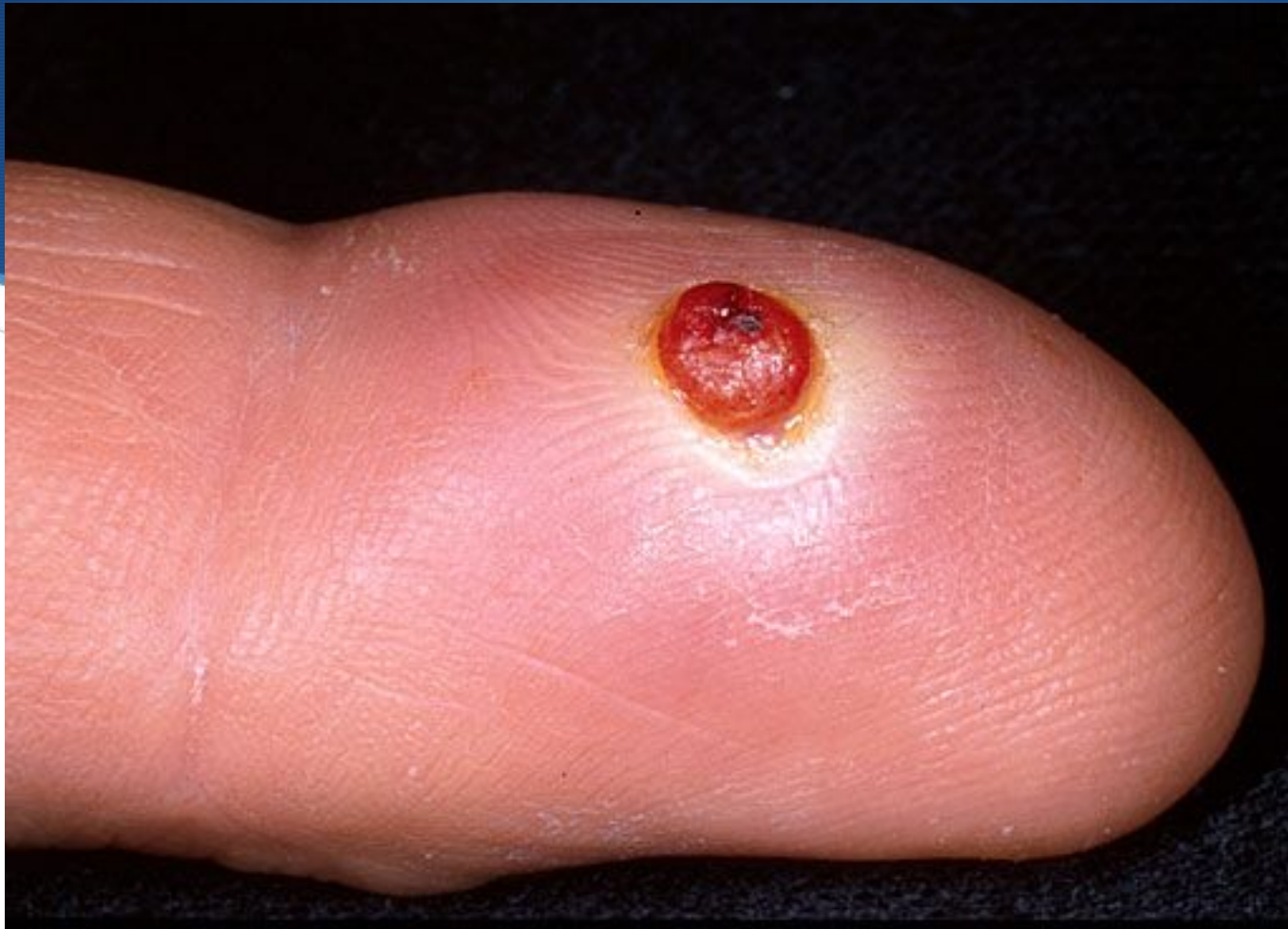DIRECTIONS FOR REMOVING EACH CAPSULE
Push through at arrow. Peel back and crumple to form a FULL TAB
x on reverse side. Proceed to Step 2 on reverse side.

AC CUTANE[®] MAY CAUSE SEVERE BIRTH DEFECTS

Spider Naevus



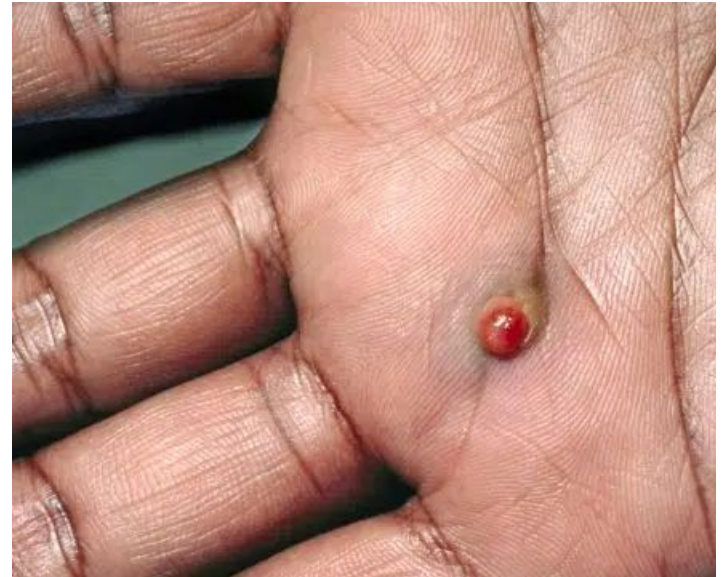



Pyogenic granuloma.....is neither

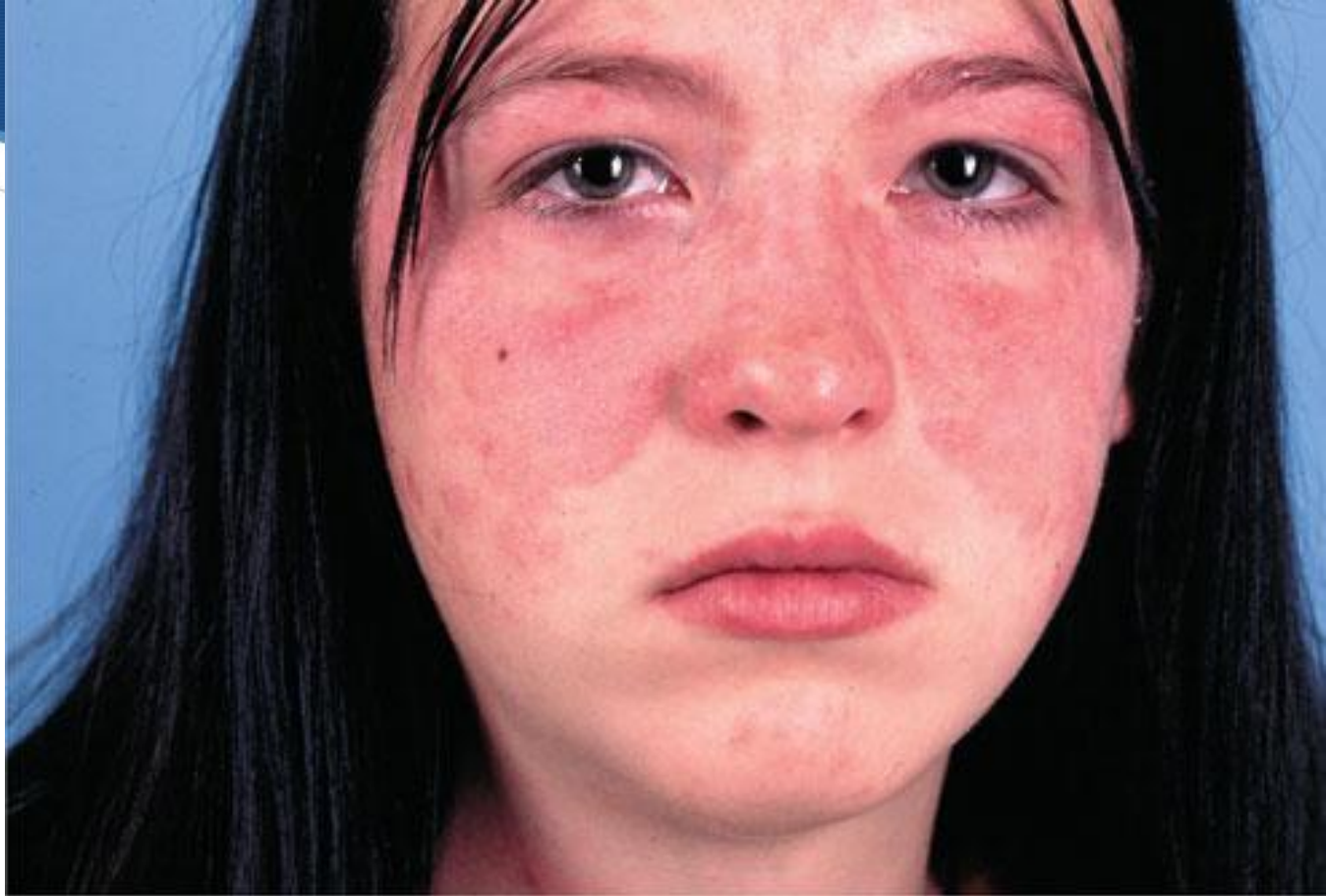Pyogenic Granuloma

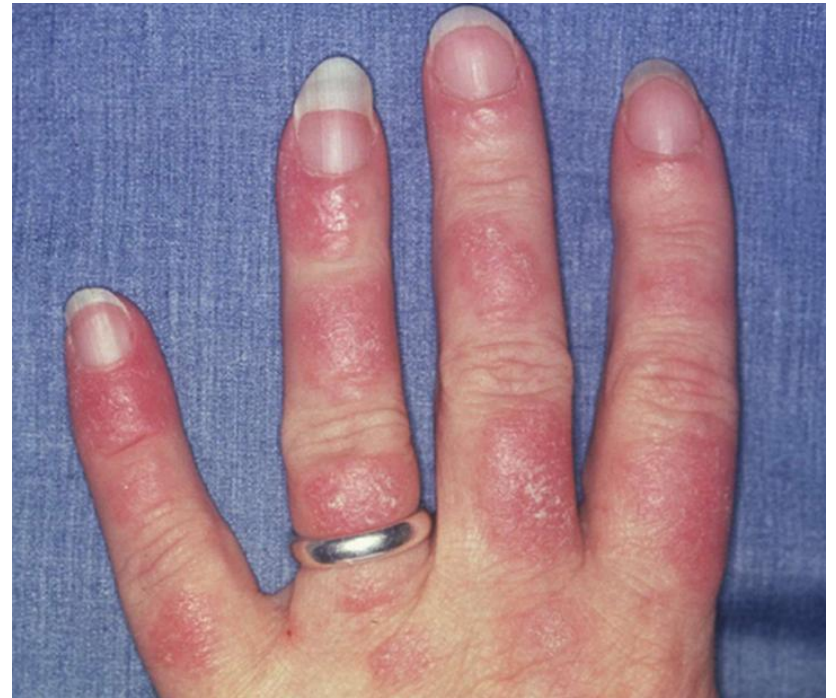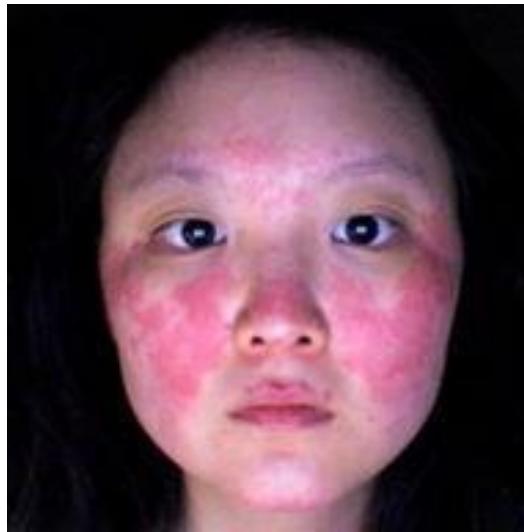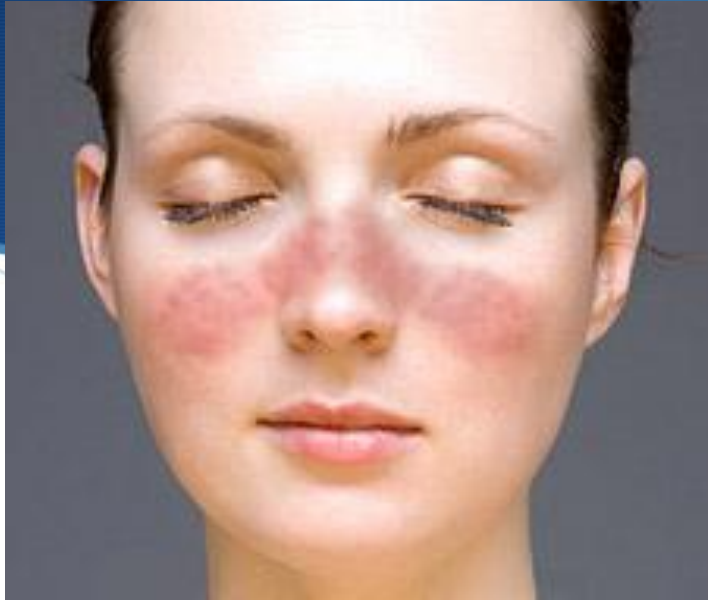- More accurately: lobular capillary hemangioma
- Exact cause unclear
 - Minor trauma
 - Infection
 - Imbalance of angiogenic factors
 - Preexisting vascular anomalies
- Treatment
 - Complete excision
 - Shave excision and electrocautery for cosmetic areas



Diseases Impacting Pregnancy

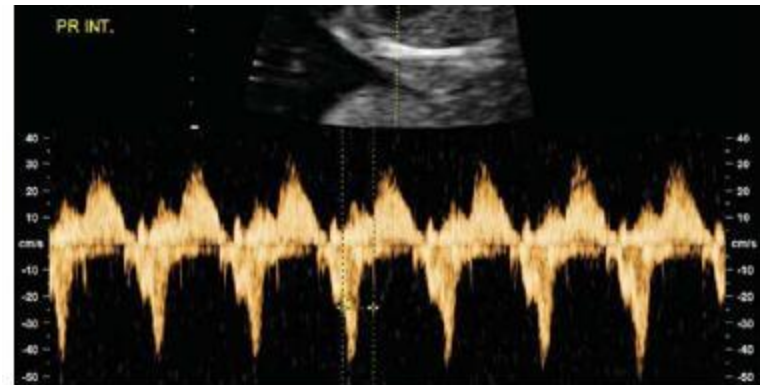
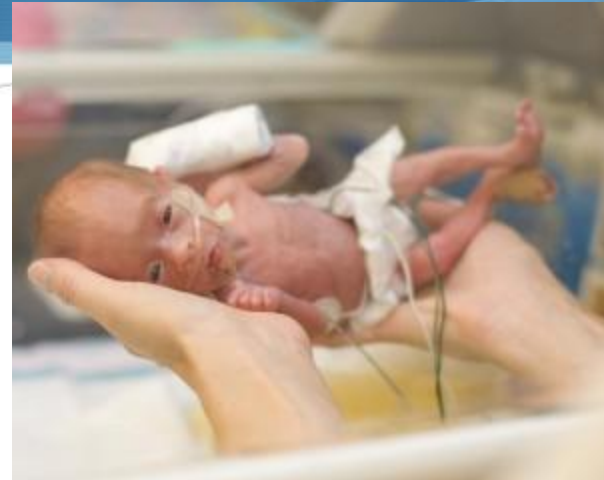


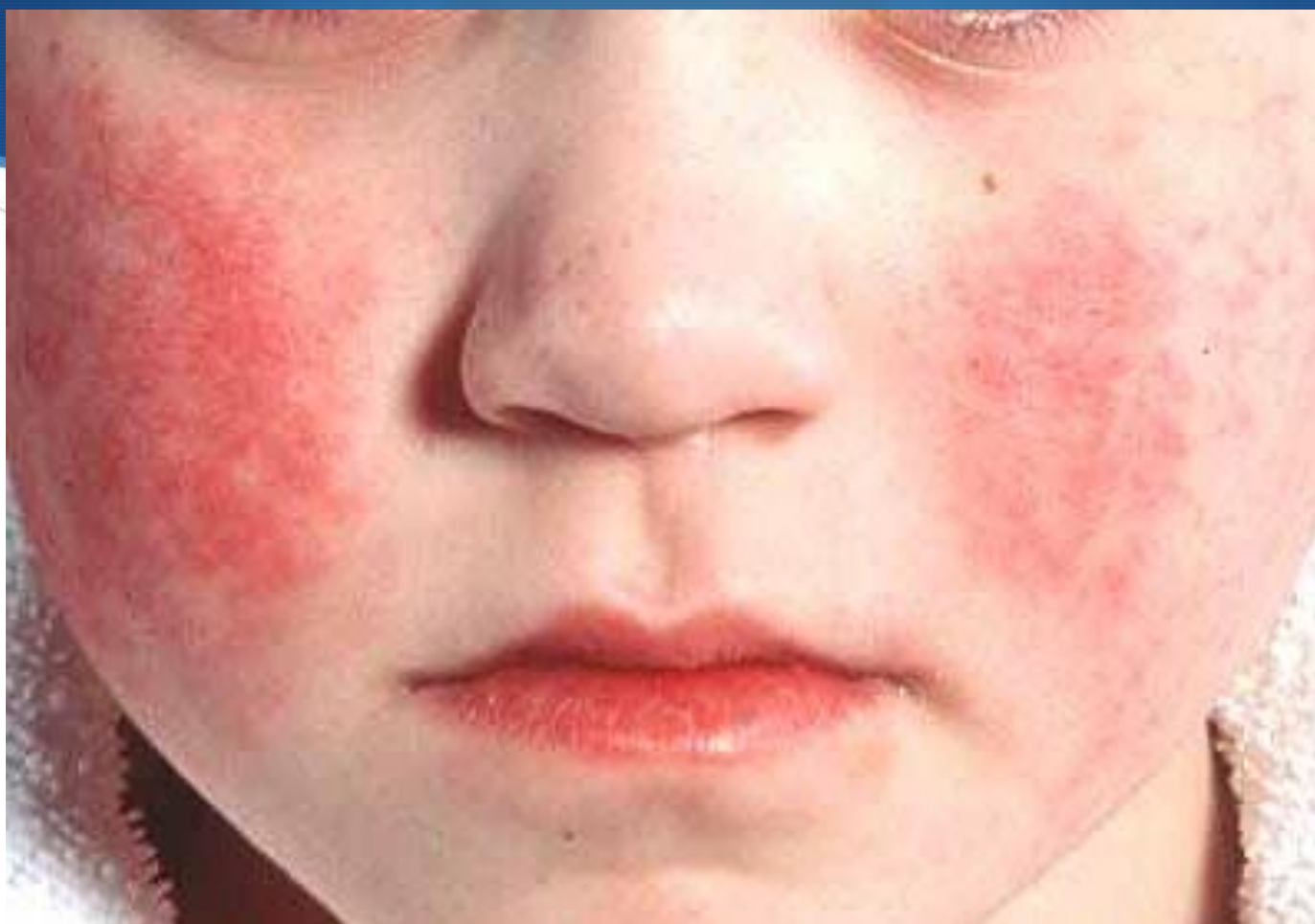
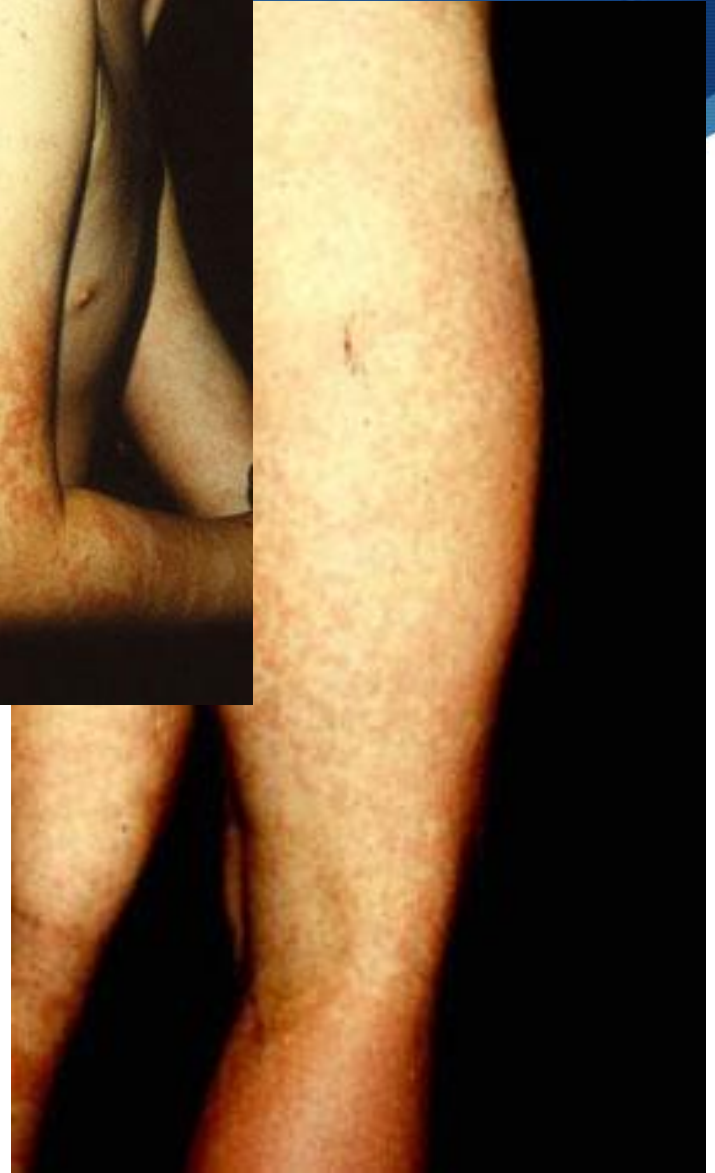


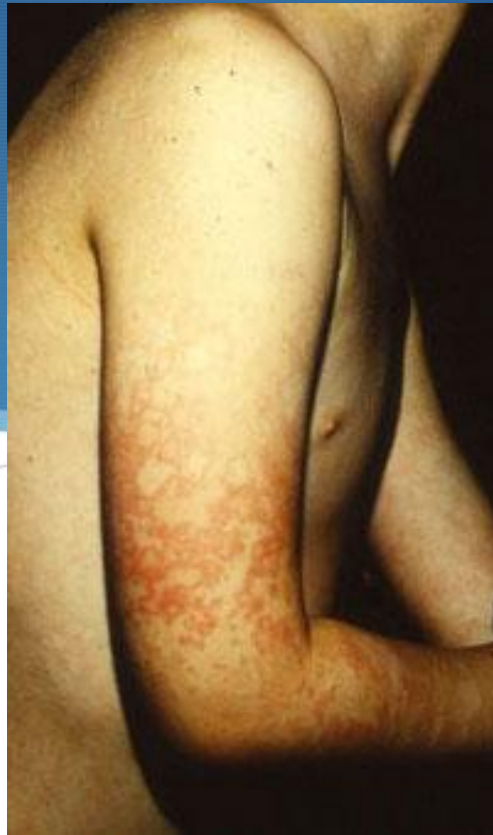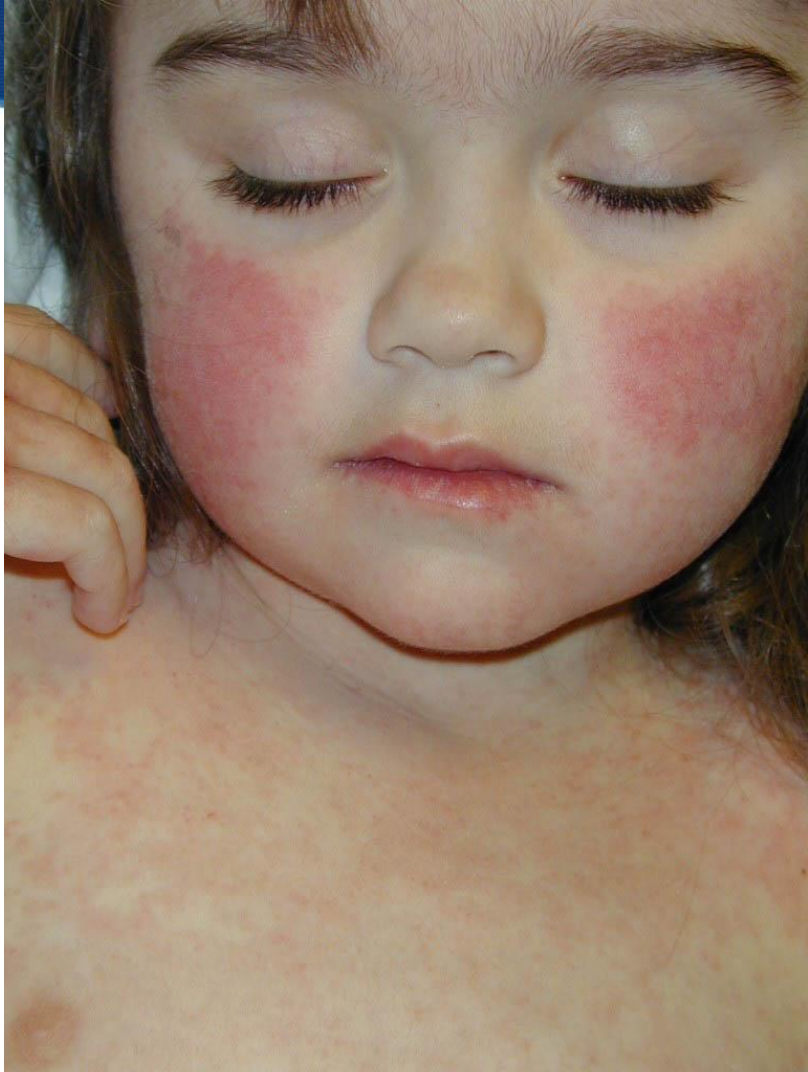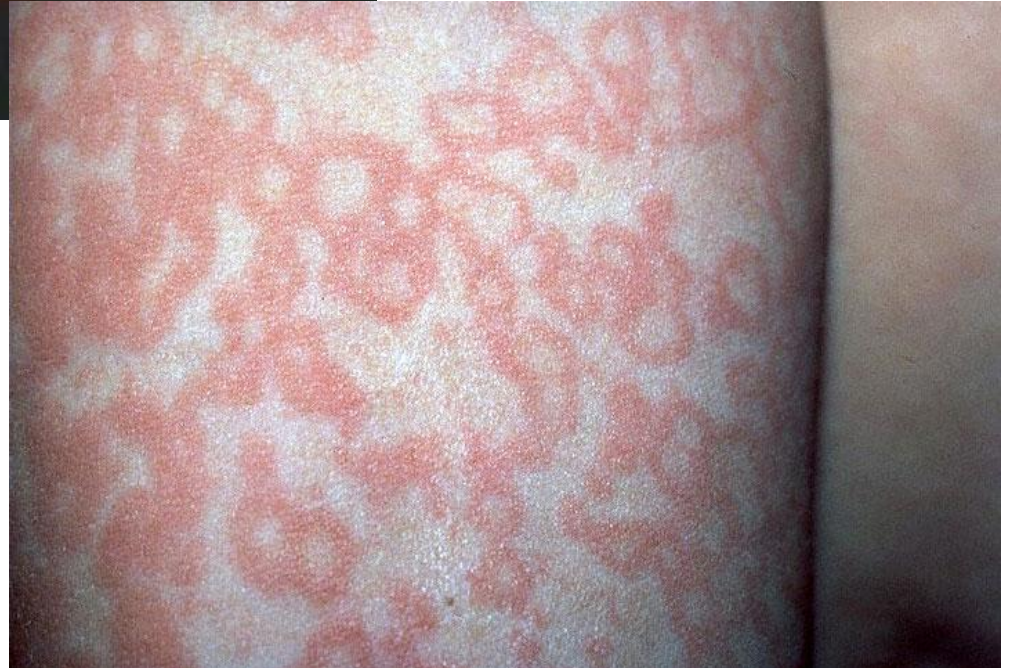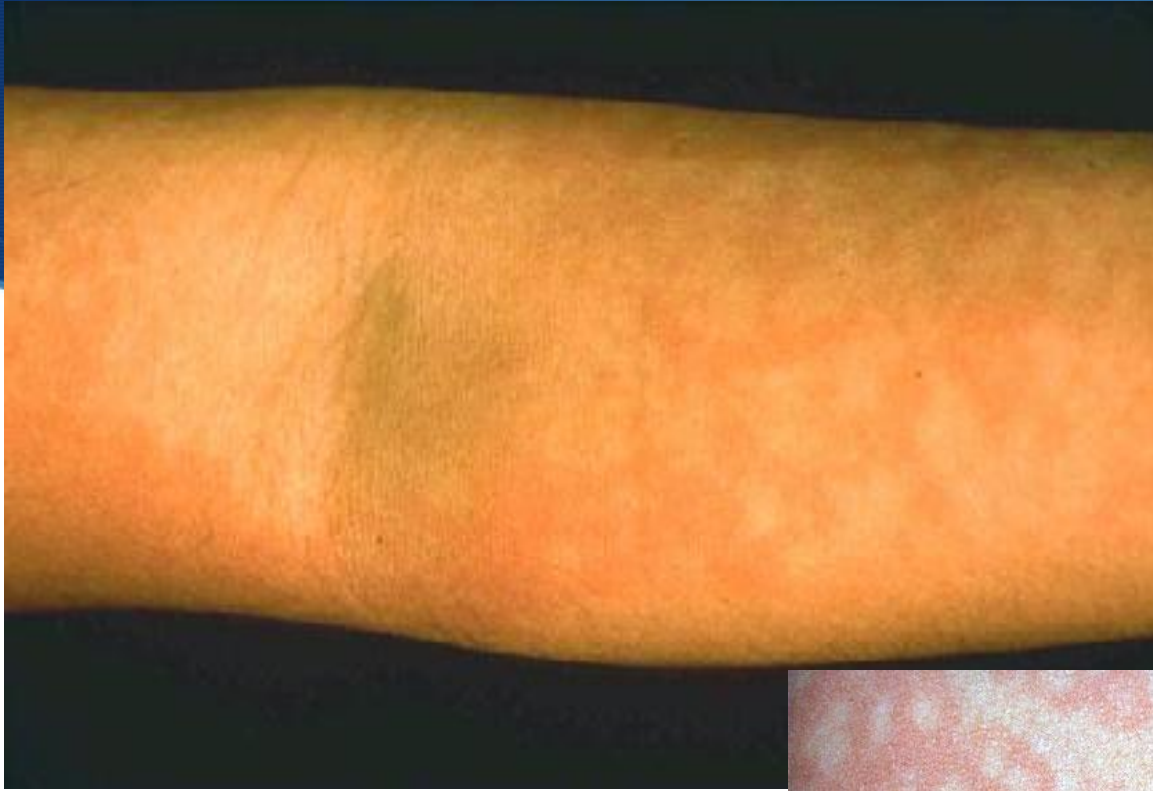Pregnancy and Lupus

- 💧 Fetal growth restriction
- 💧 Increased fetal loss
- 💧 Worsening of SLE
- 💧 Neonatal SLE
- 💧 Preterm delivery
- 💧 Fetal heart block



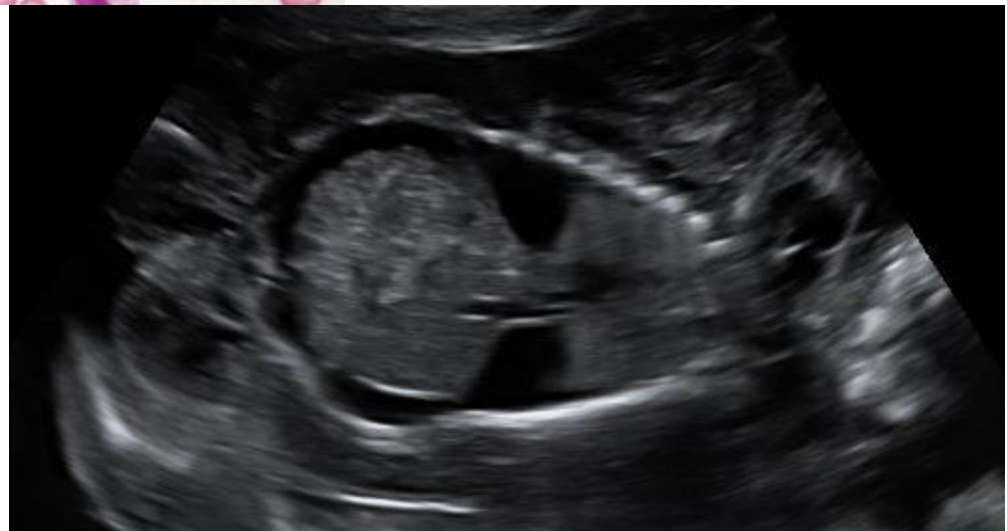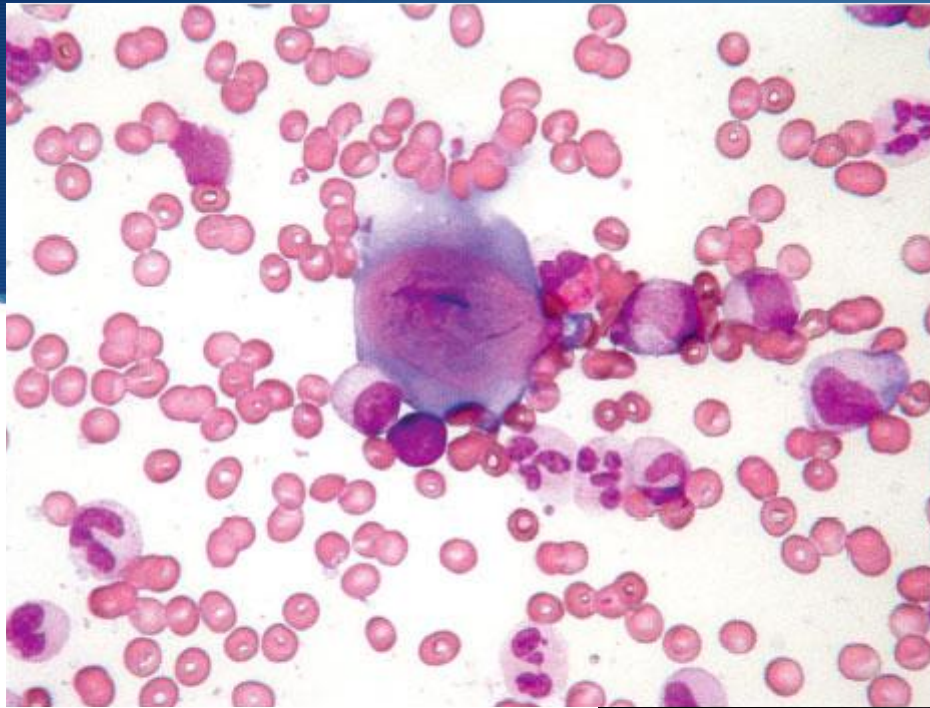



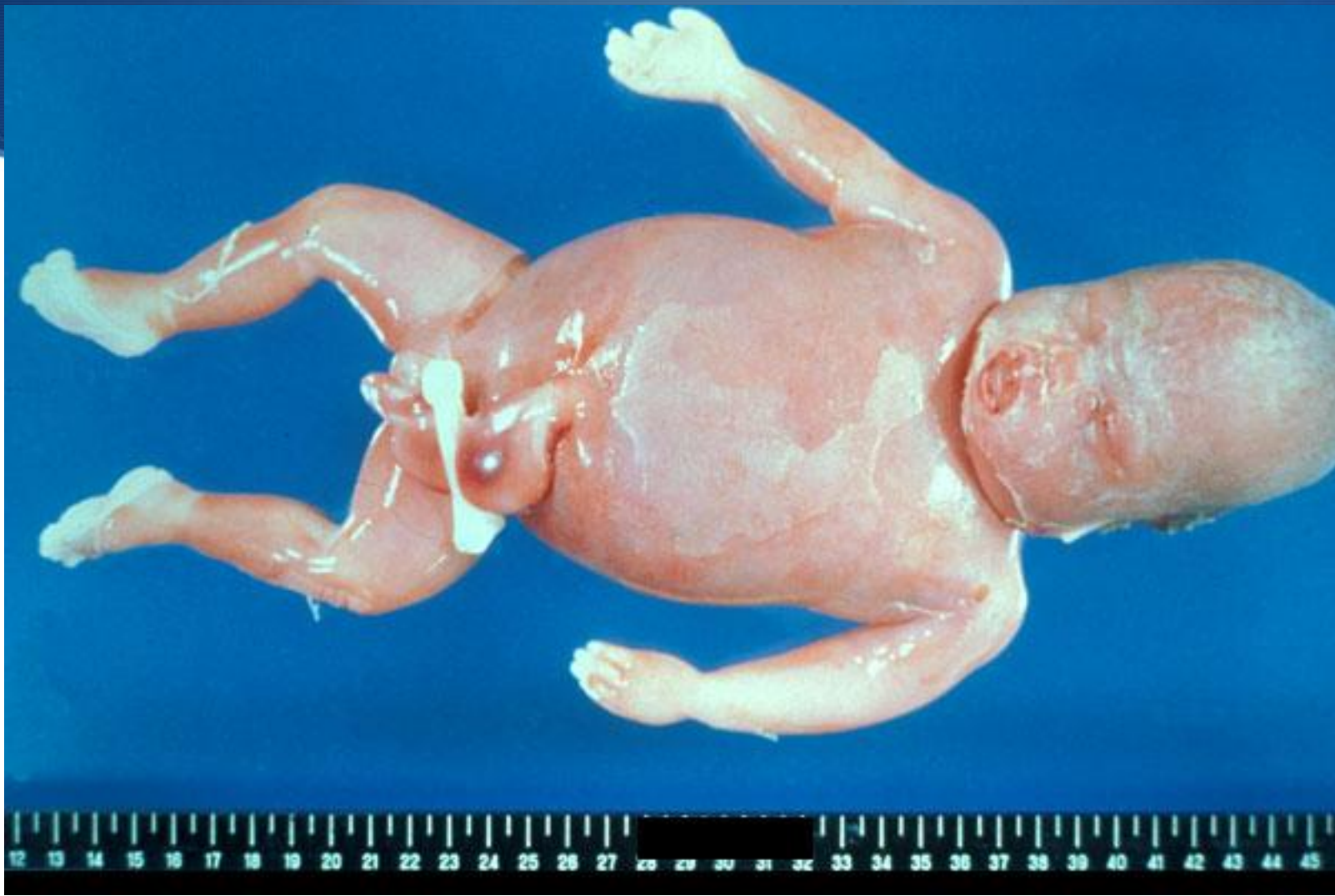
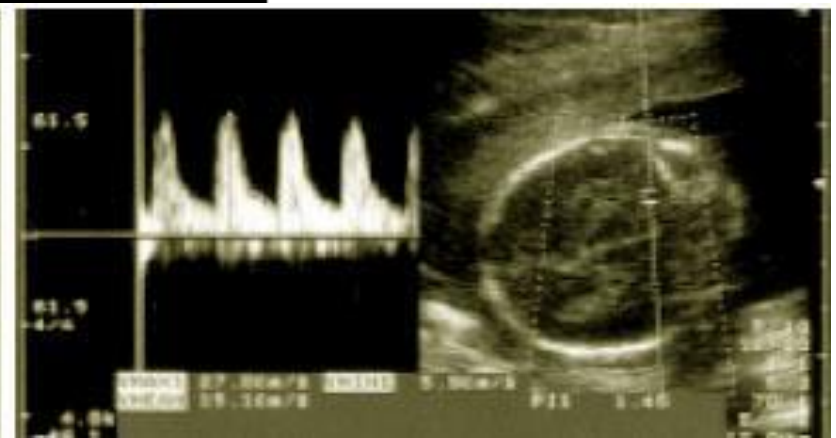
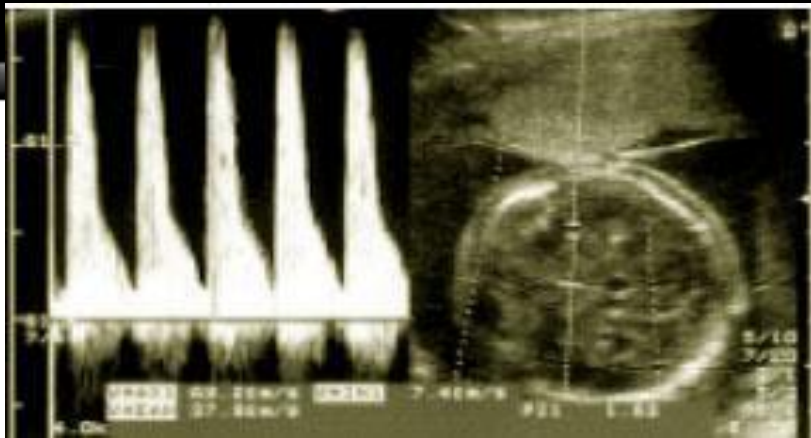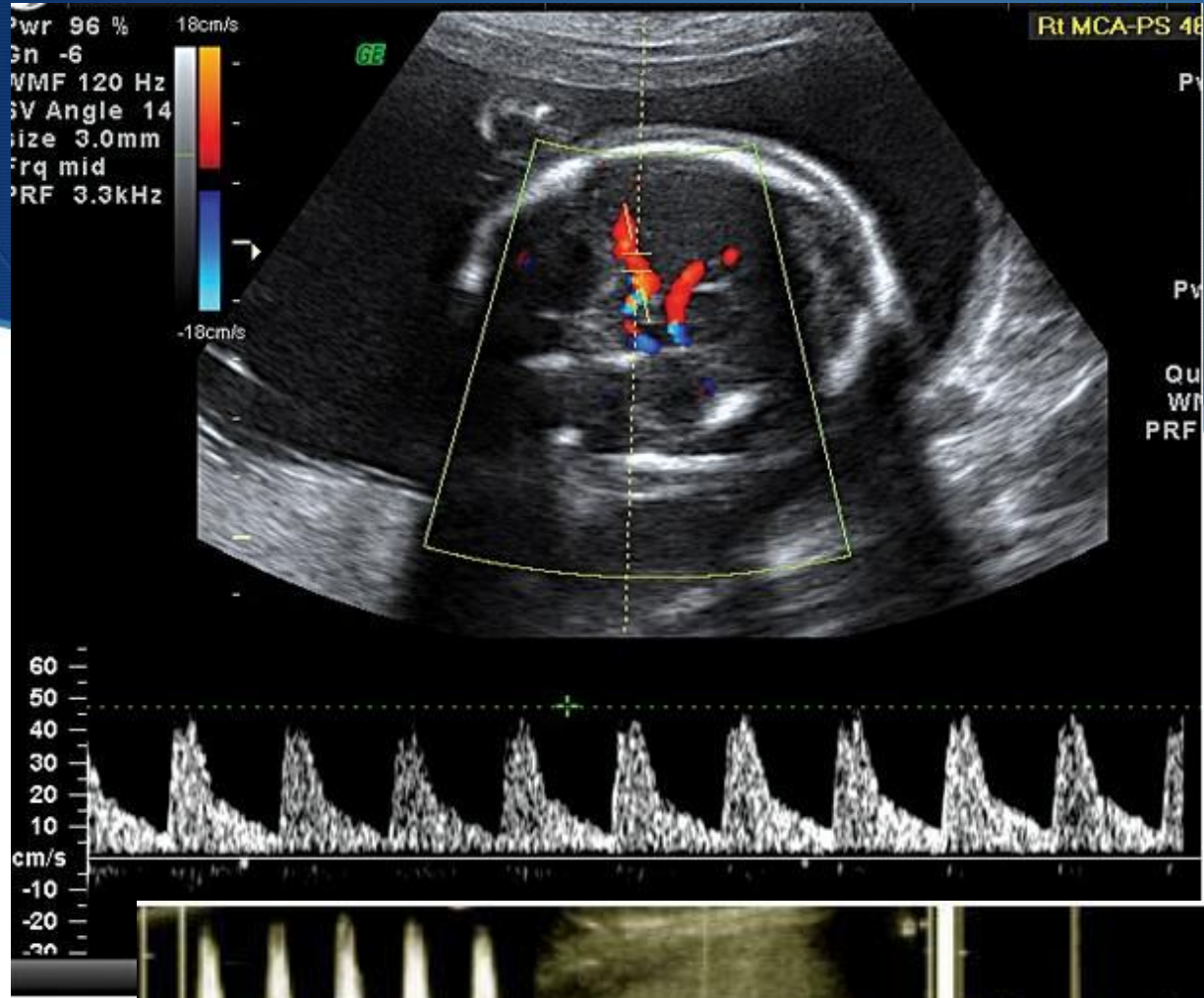


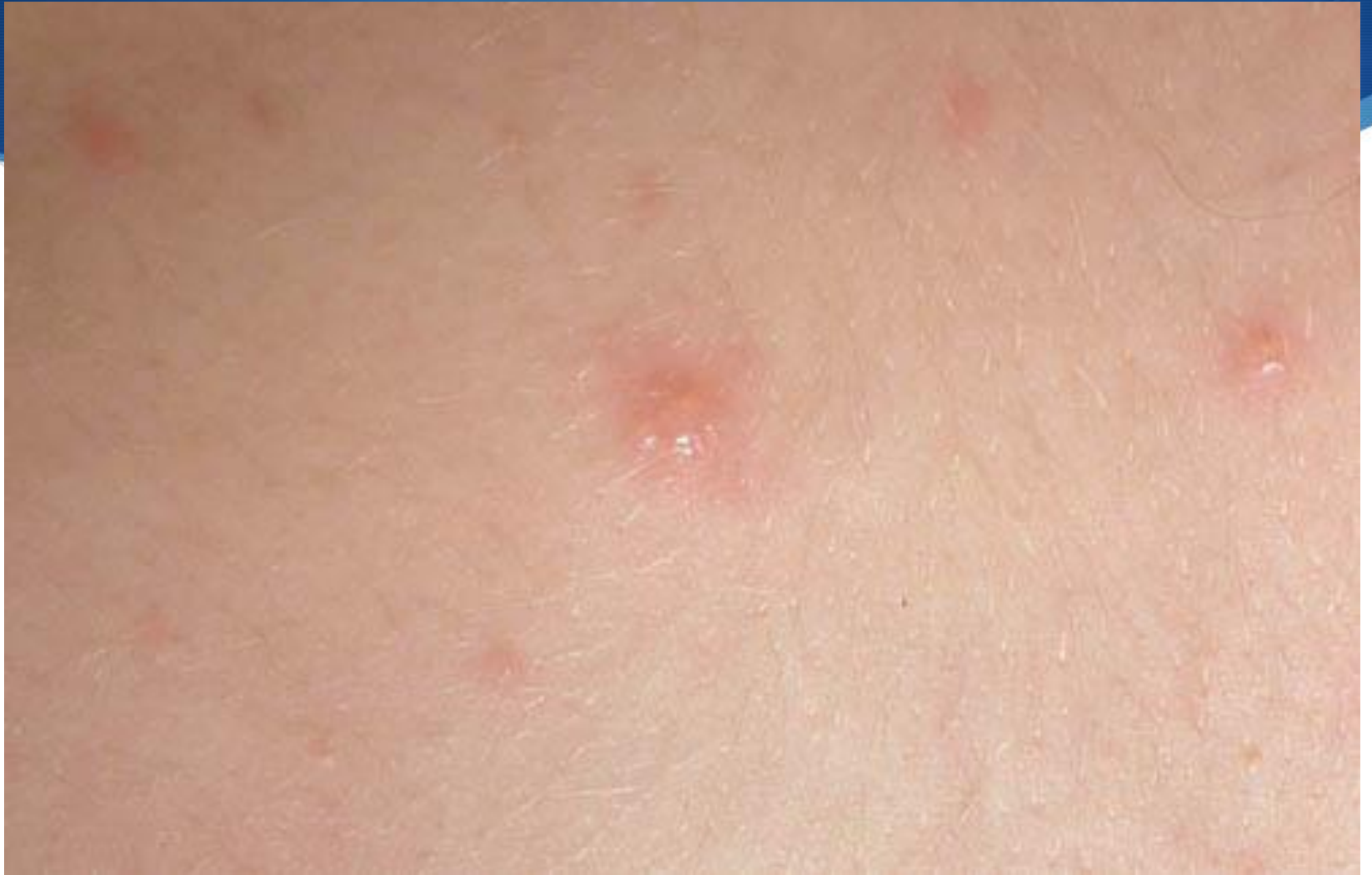Fifth Disease

Measles (rubeola)	"first disease"	measles virus
Scarlet fever	"second disease"	<i>Streptococcus pyogenes</i>
Rubella	"third disease"	rubella virus
(disputed)	"fourth disease"	<i>Staphylococcus aureus</i>
Erythema infectiosum	"fifth disease"	parvovirus B19
Roseola infantum	"sixth disease"	HHV-6 and HHV-7

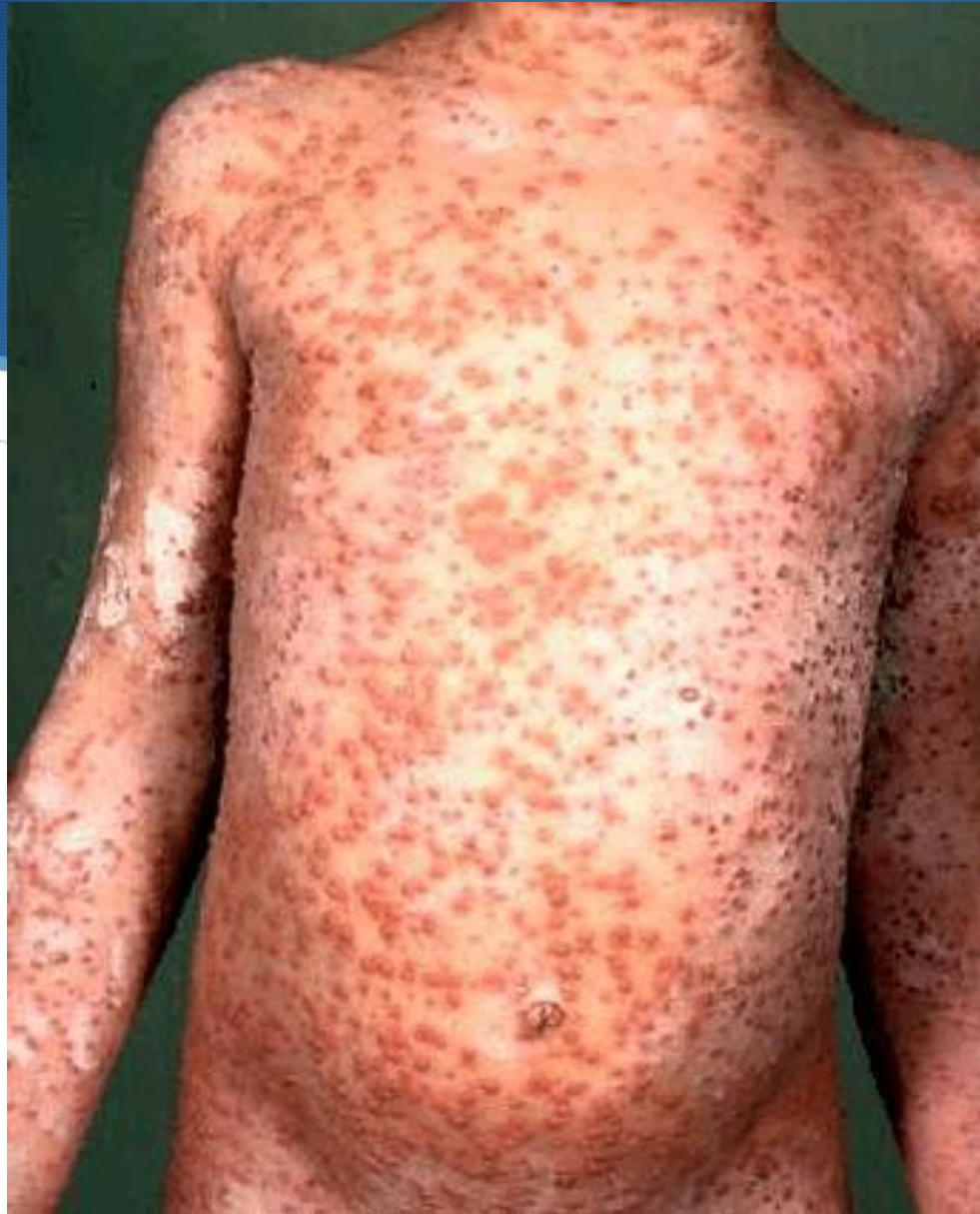



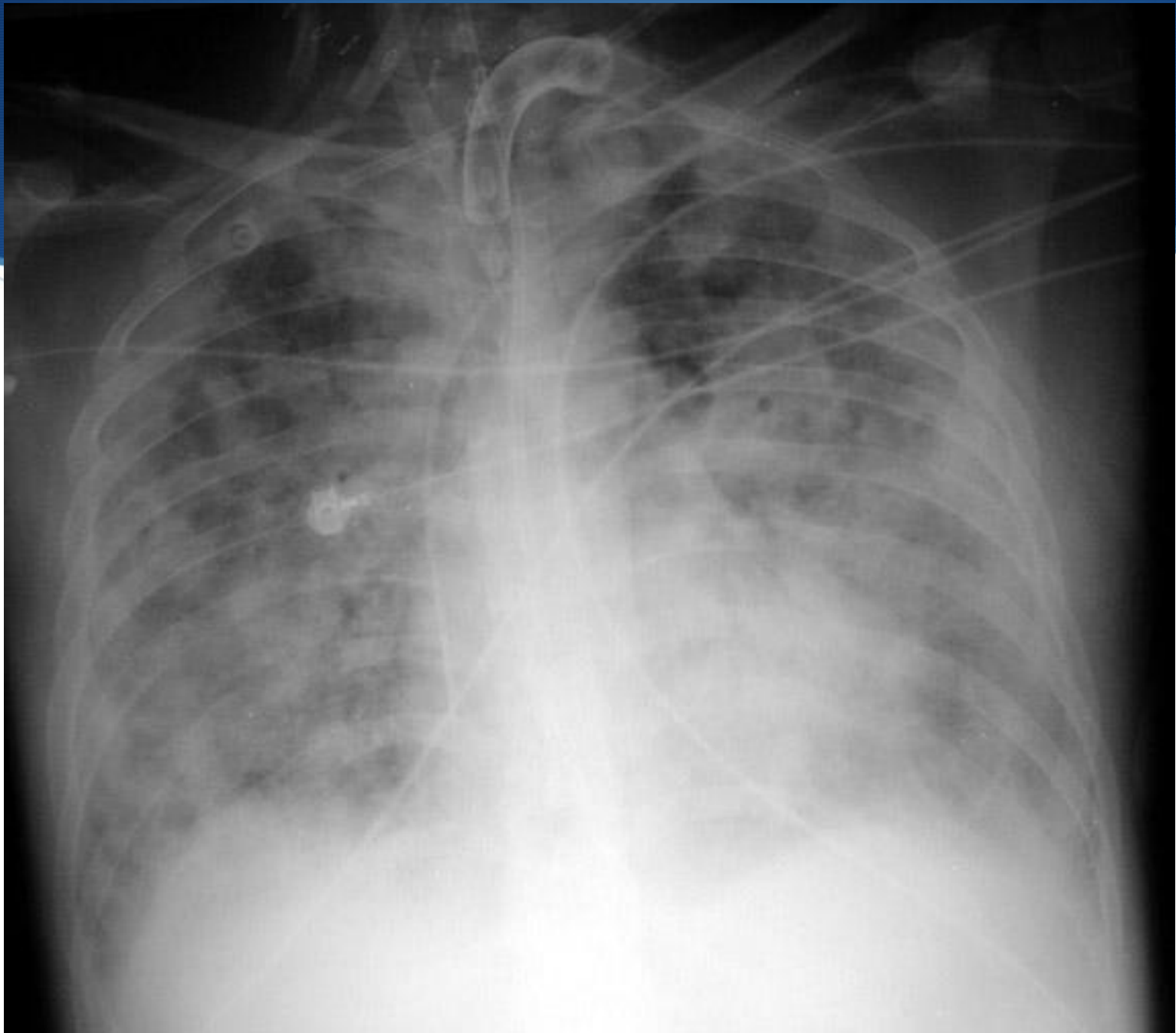




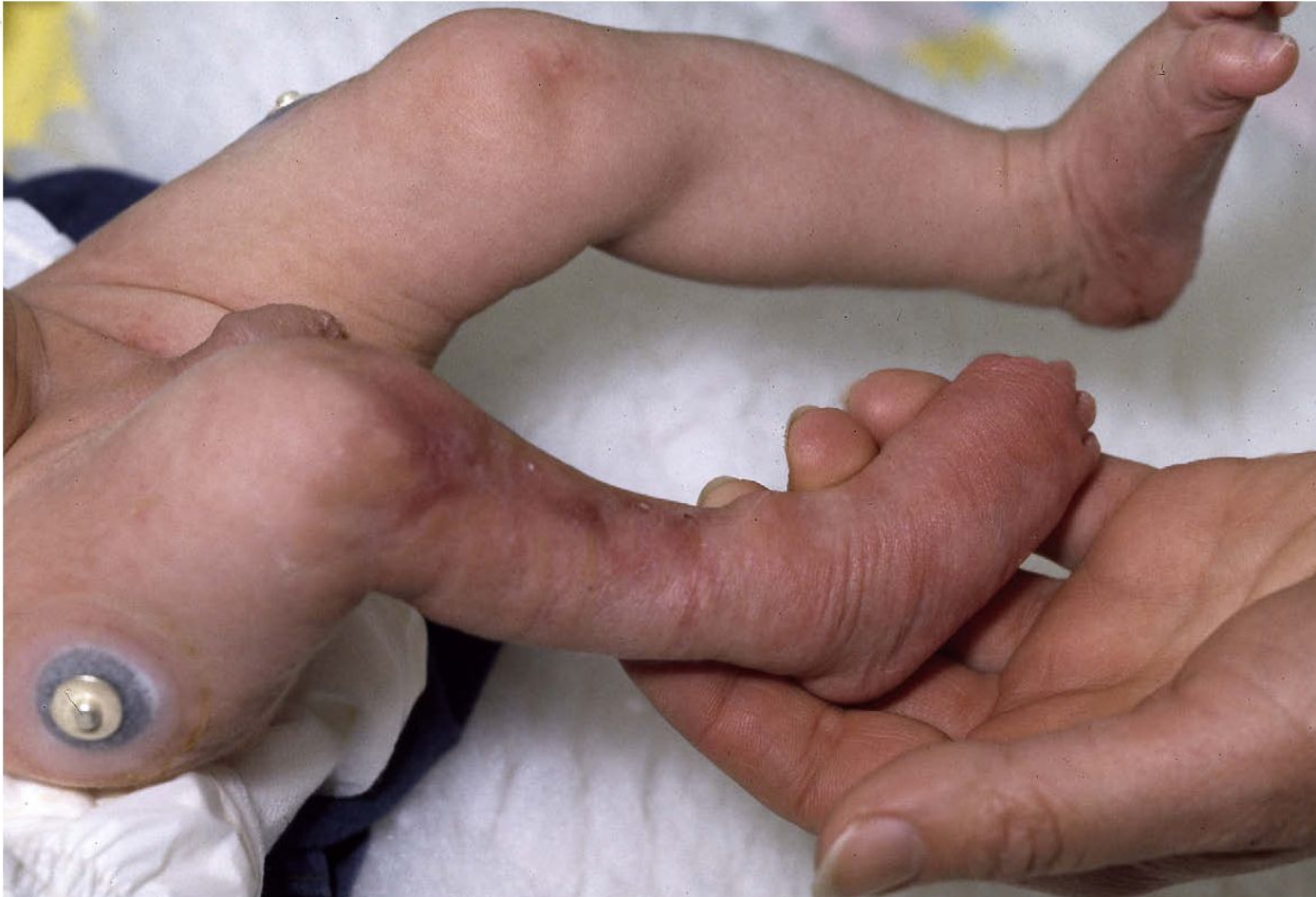Dew Drop on a rose petal = ?

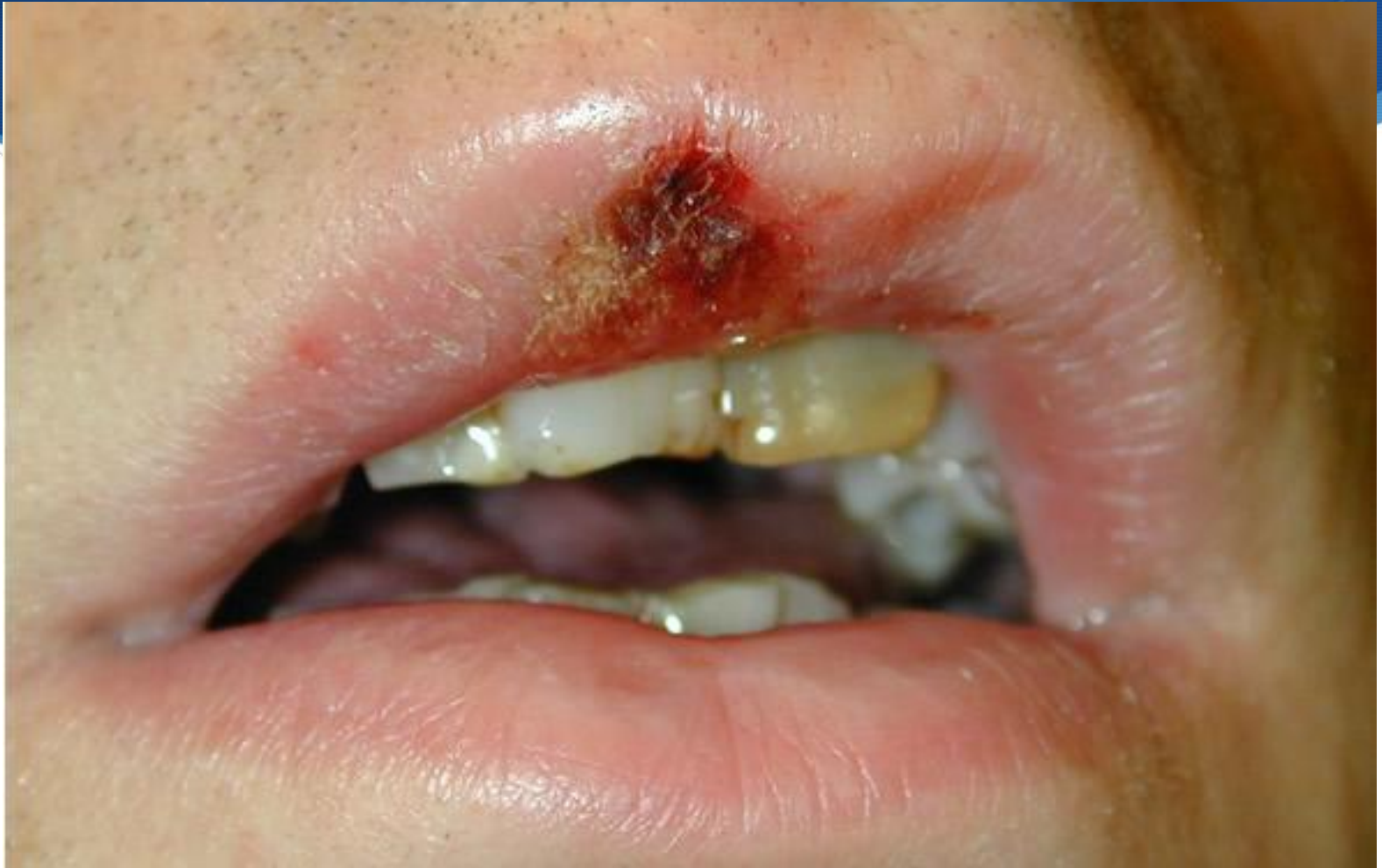

Varicella




Varicella Zoster Virus





Looks painful, but it isn't! What is it?



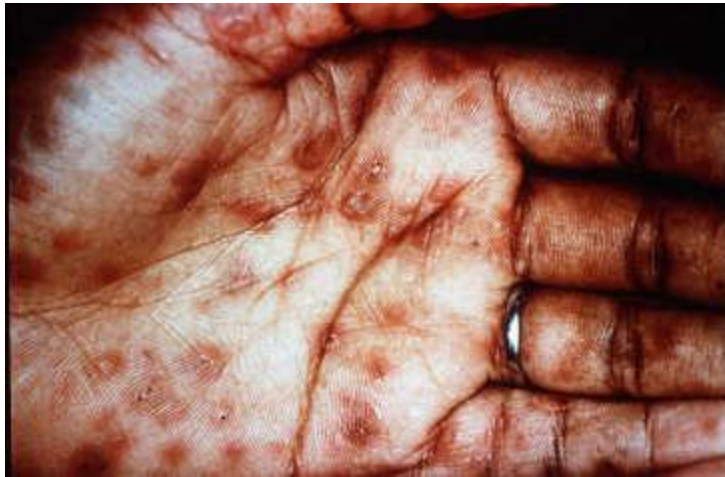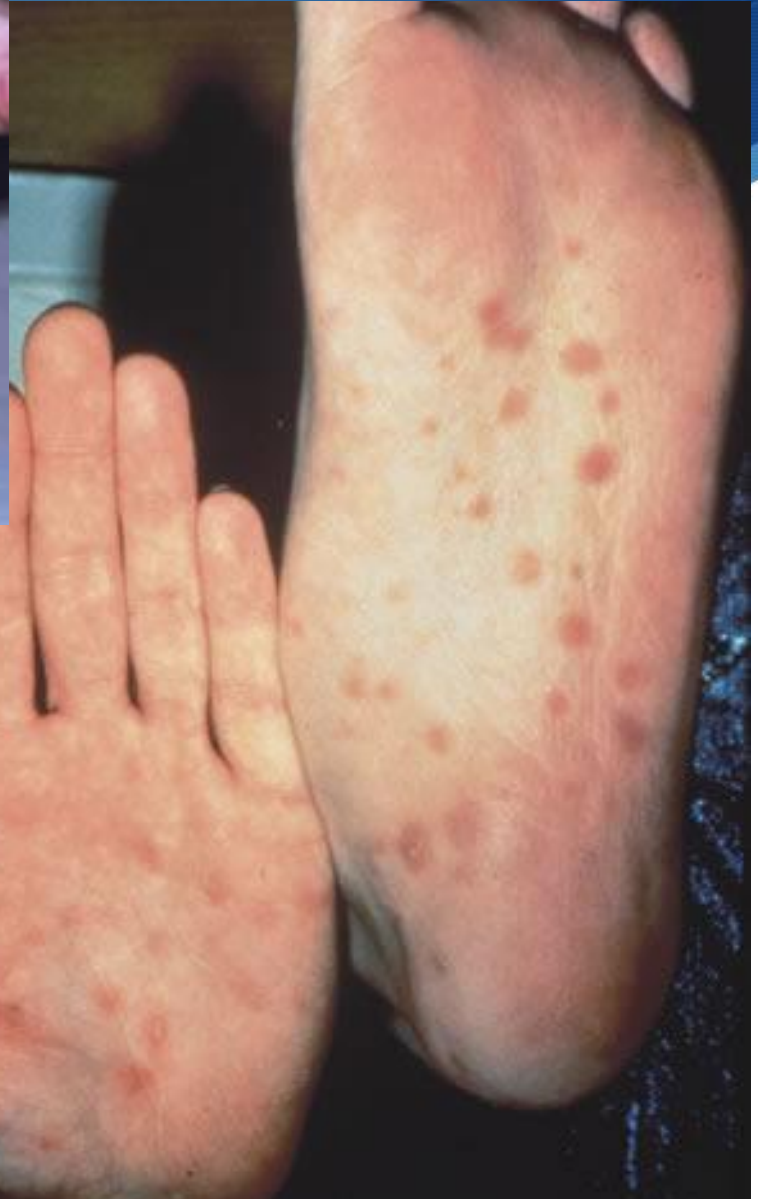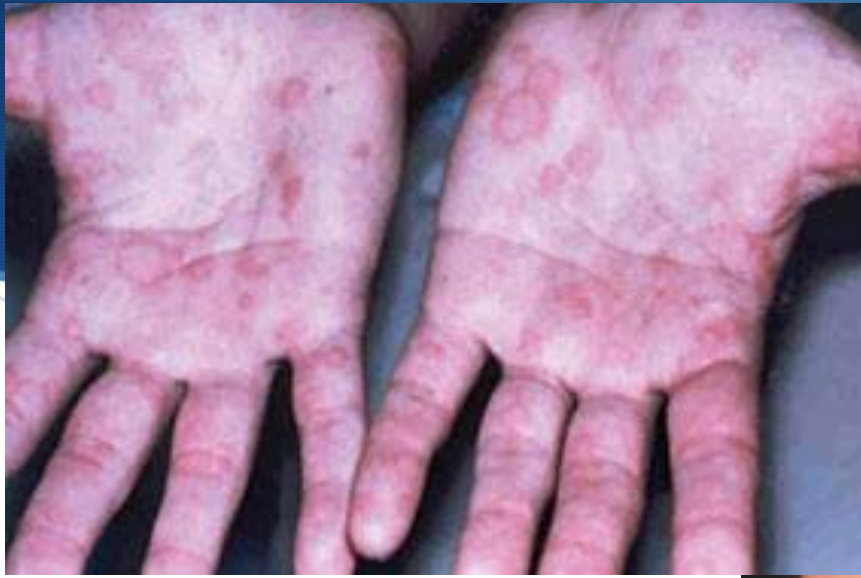The syphilis bacterium
Treponema pallidum

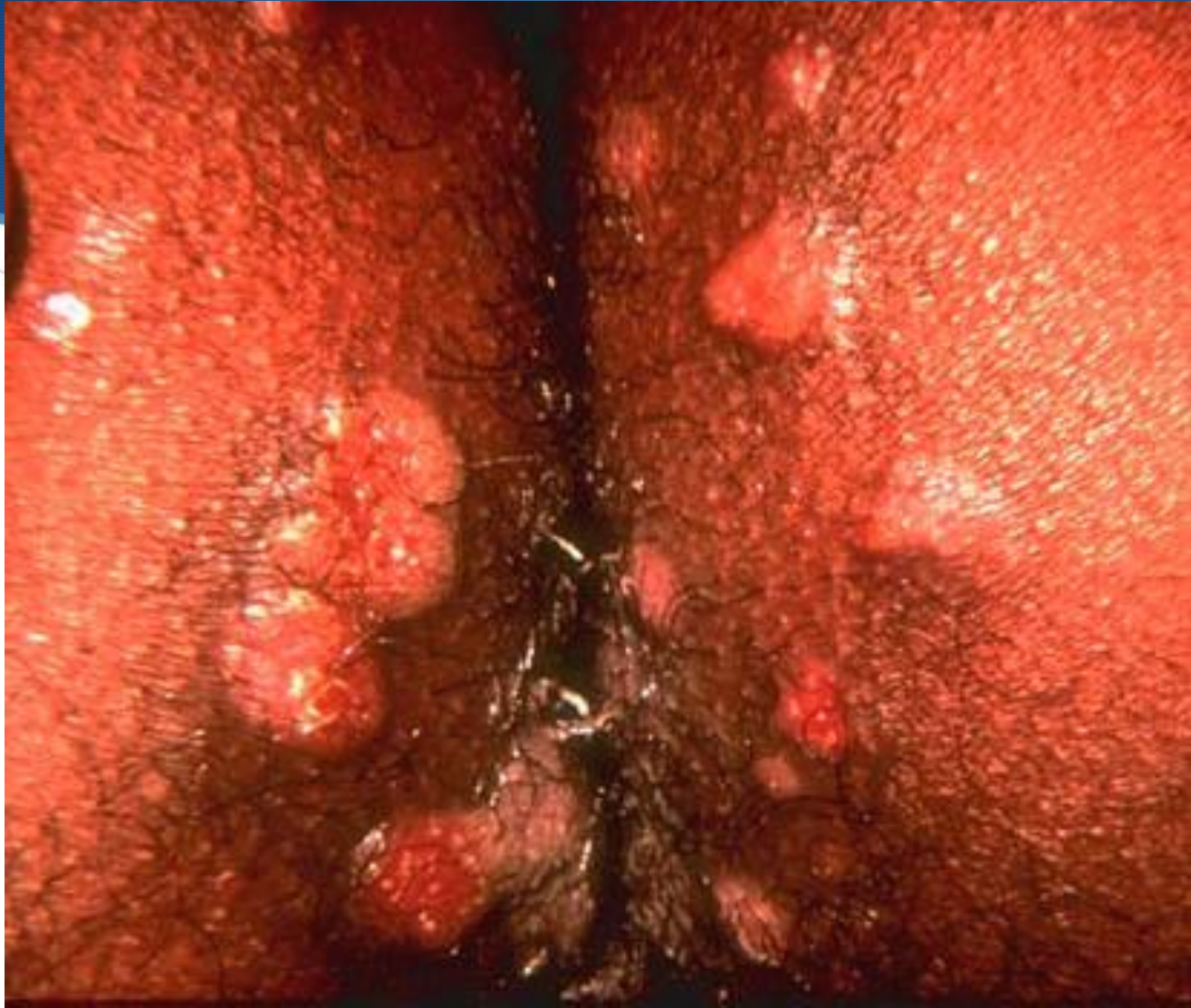

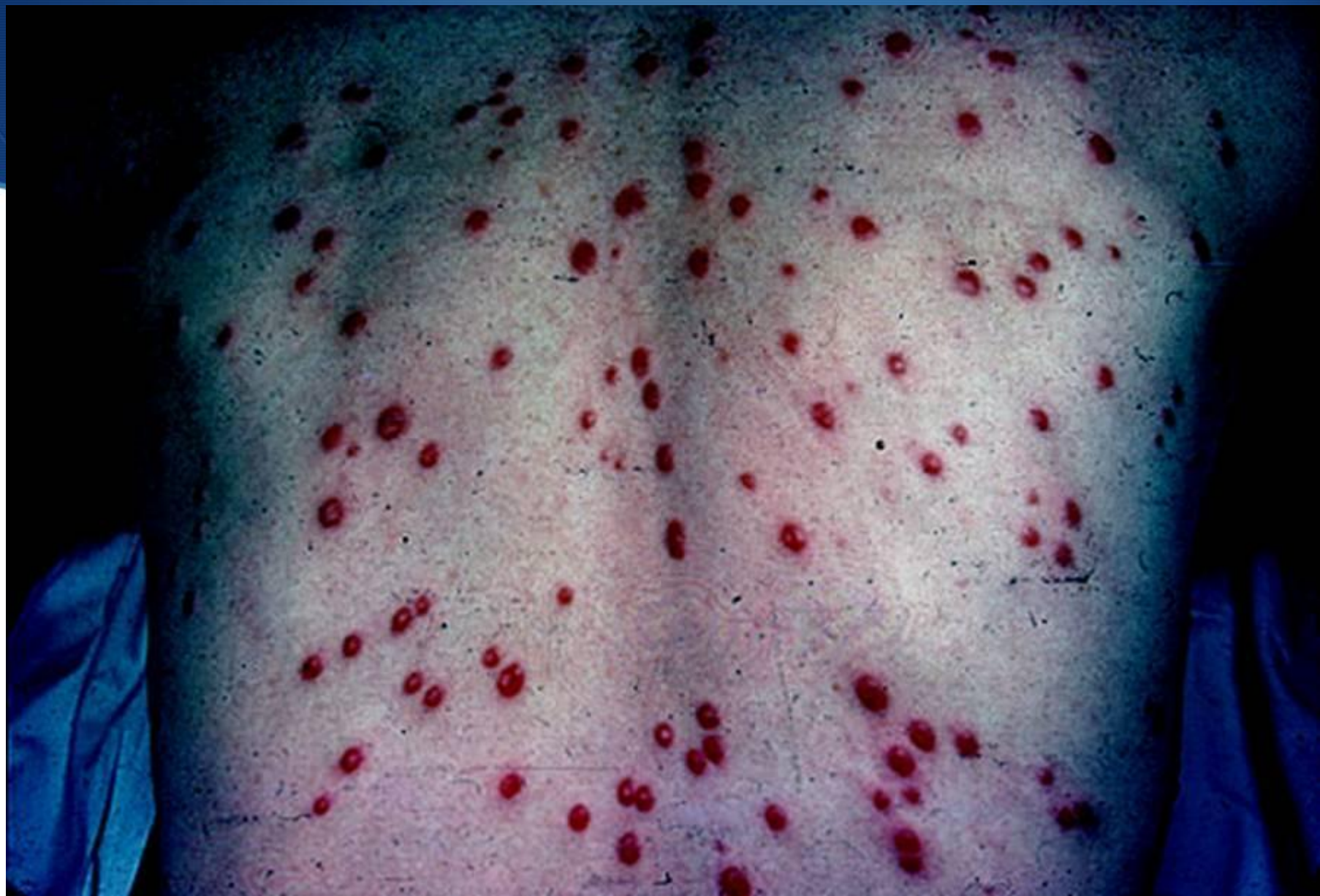John Dillinger

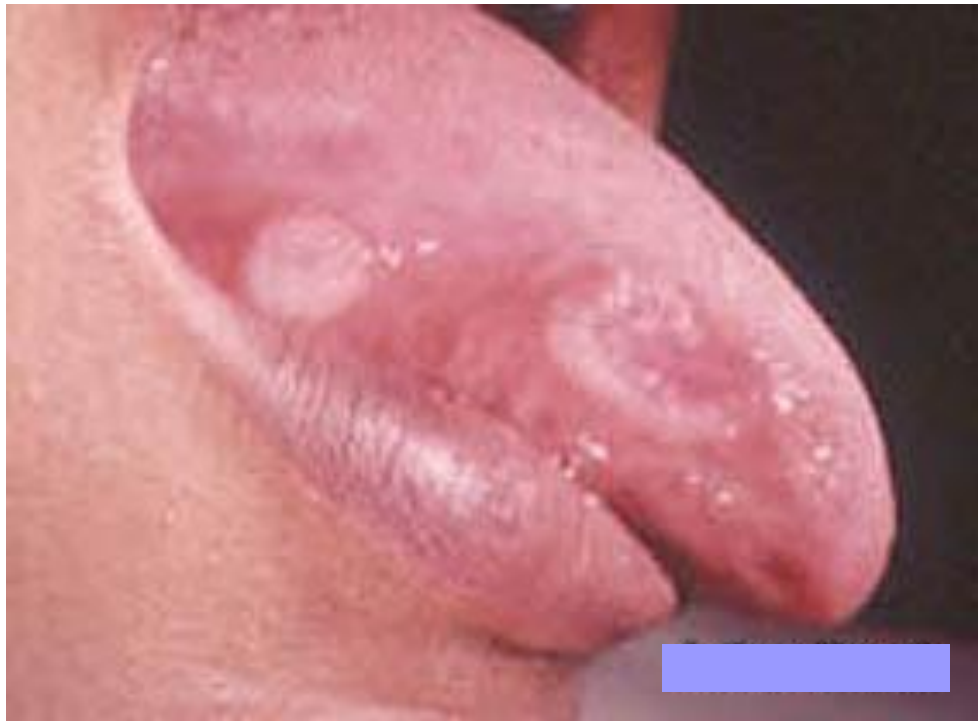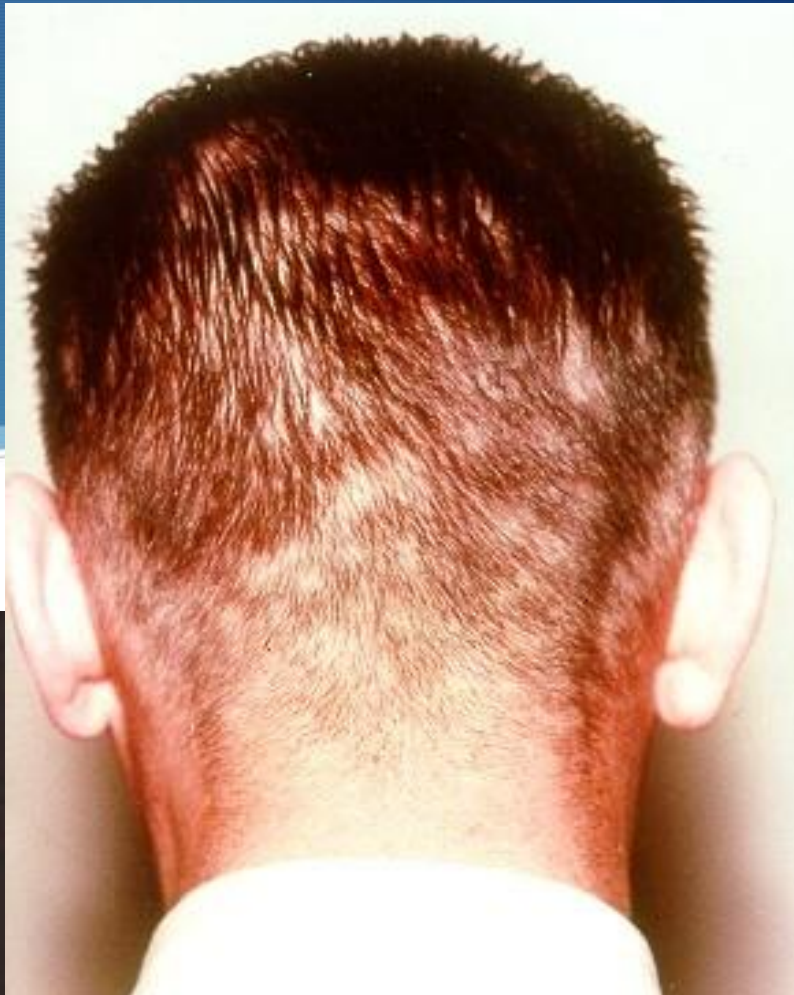13225

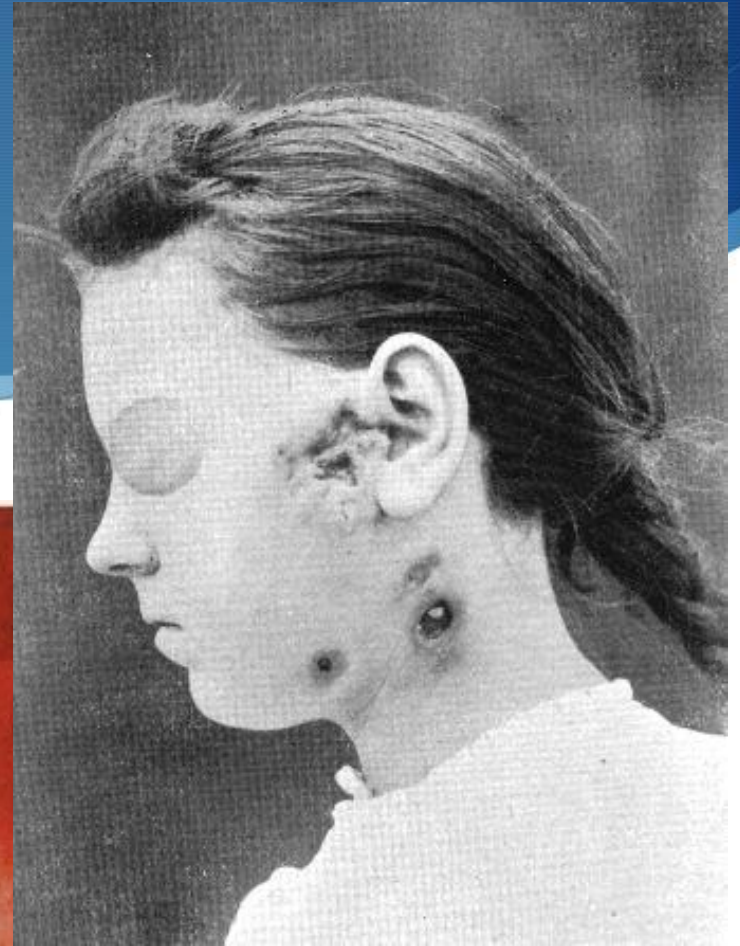
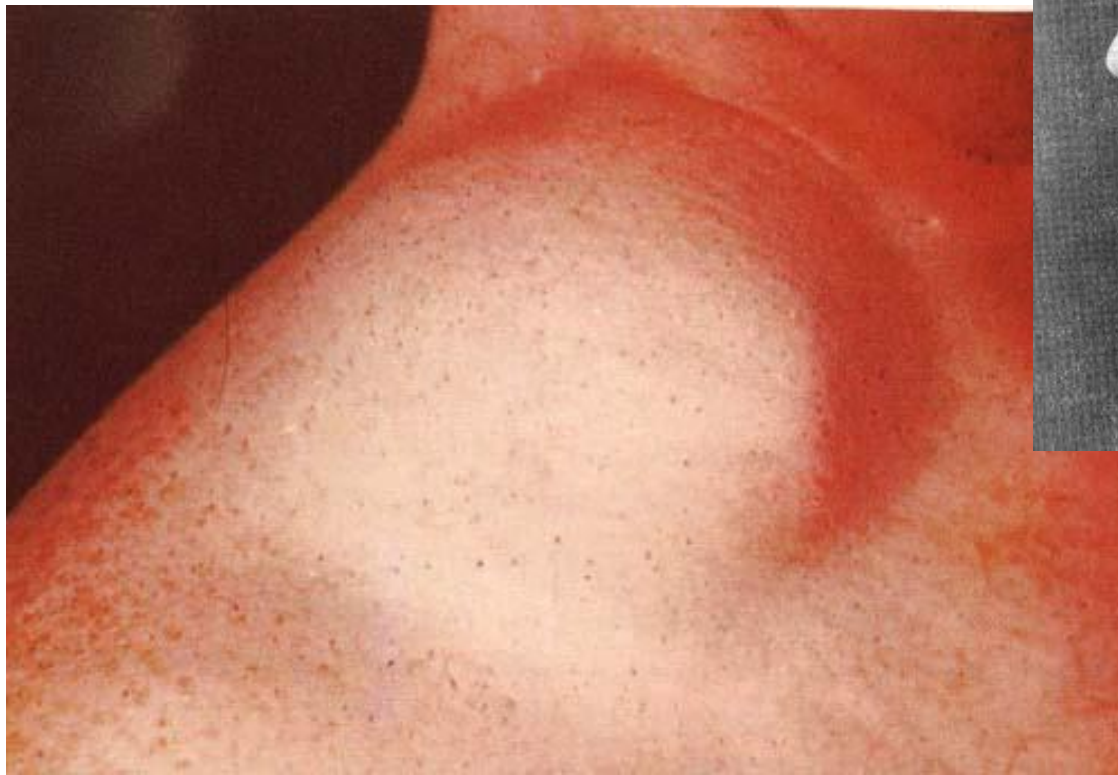


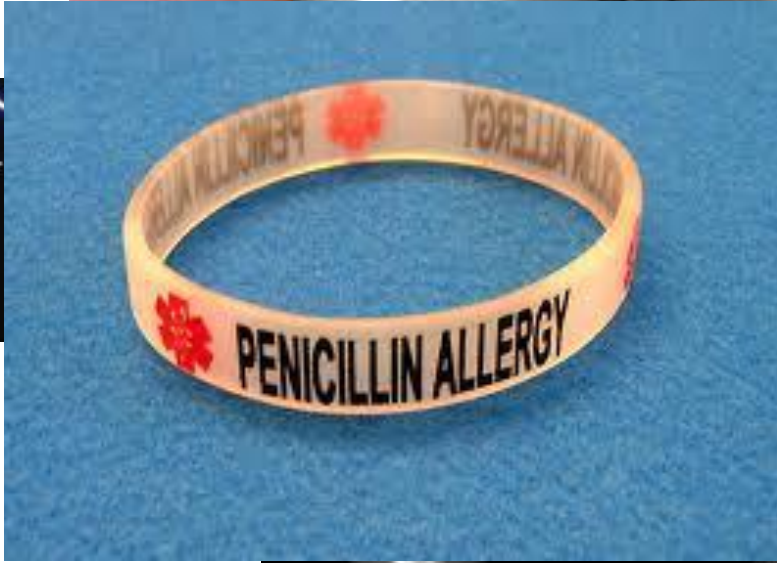
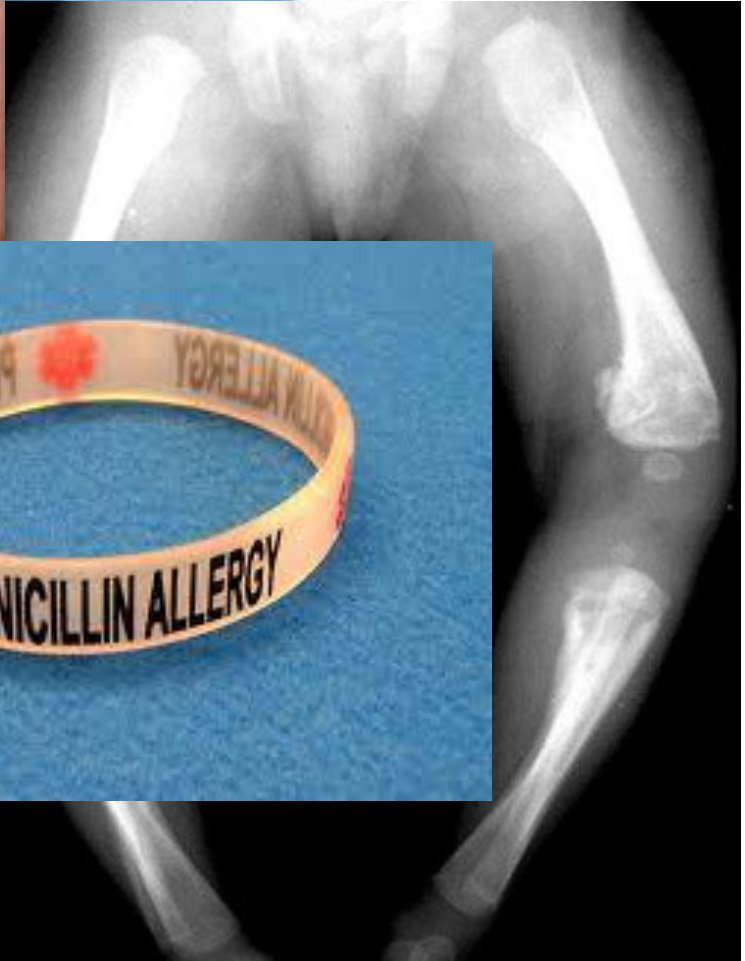
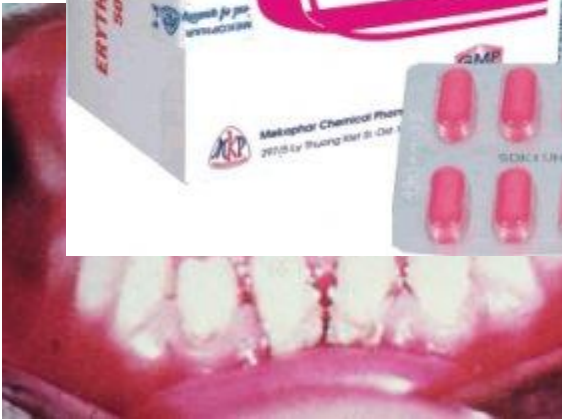
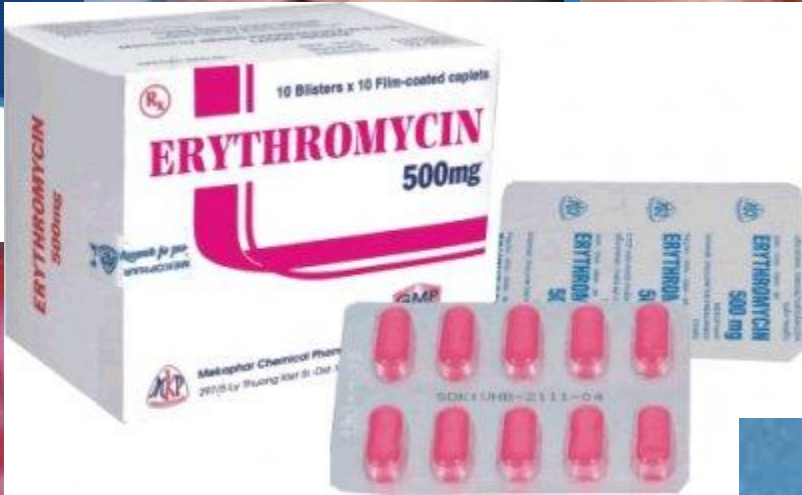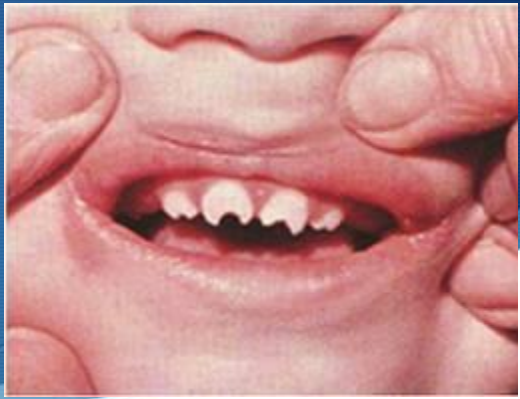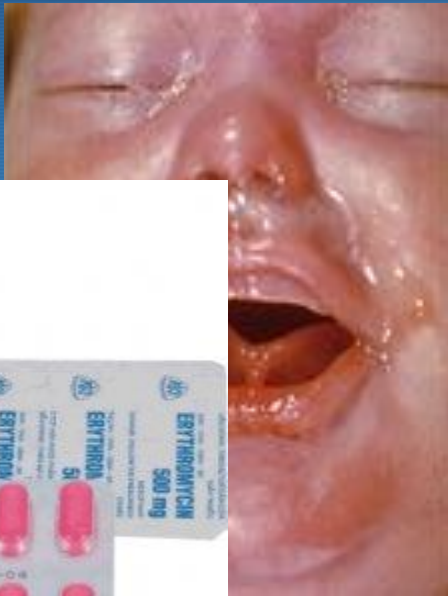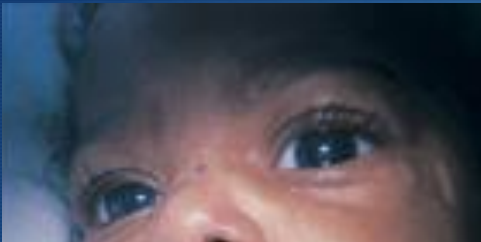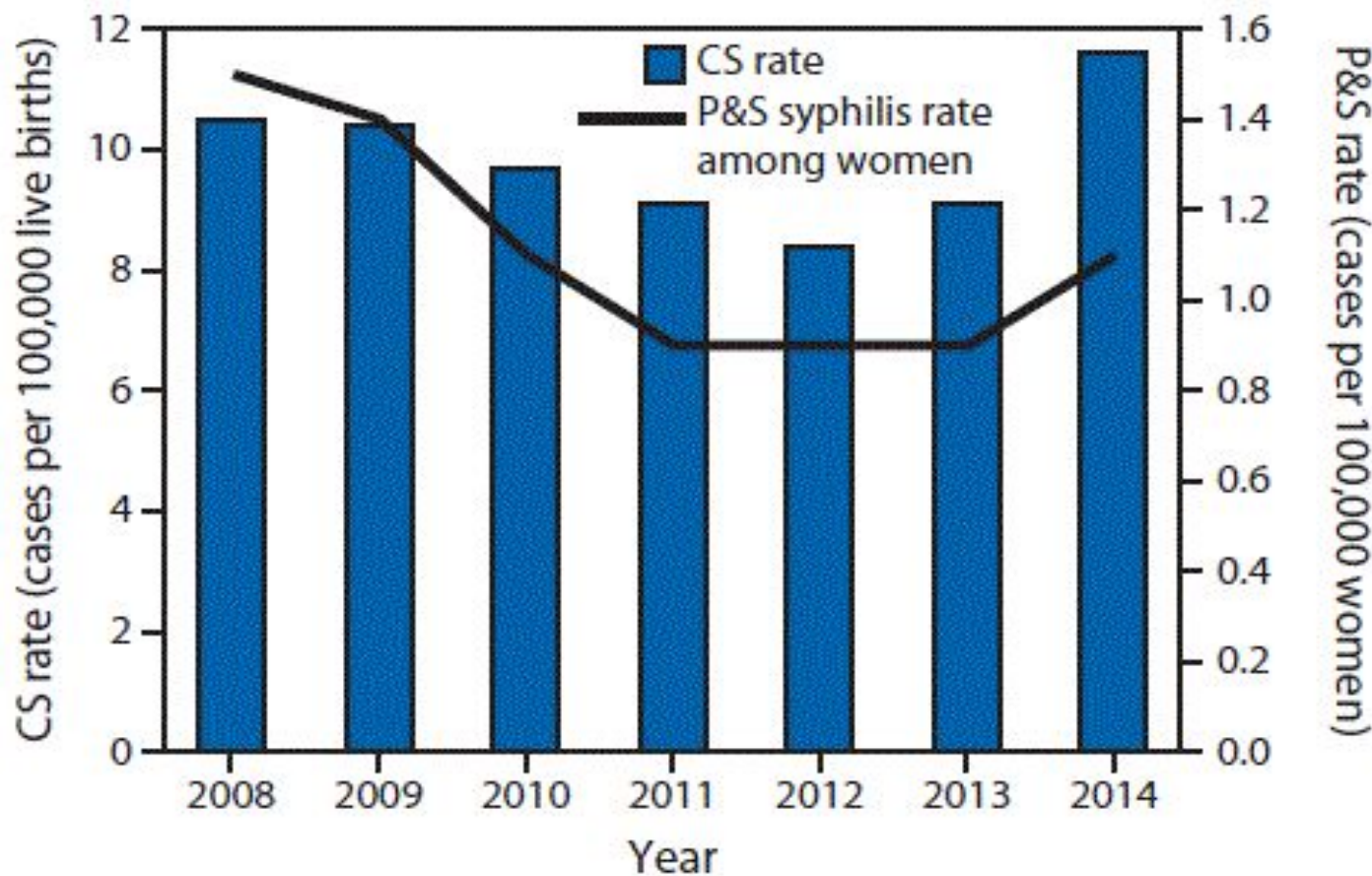








Congenital Syphilis—Reported Cases Among Infants by Year of Birth and Rates of Primary and Secondary Syphilis Among Women, United States, 2002—2011

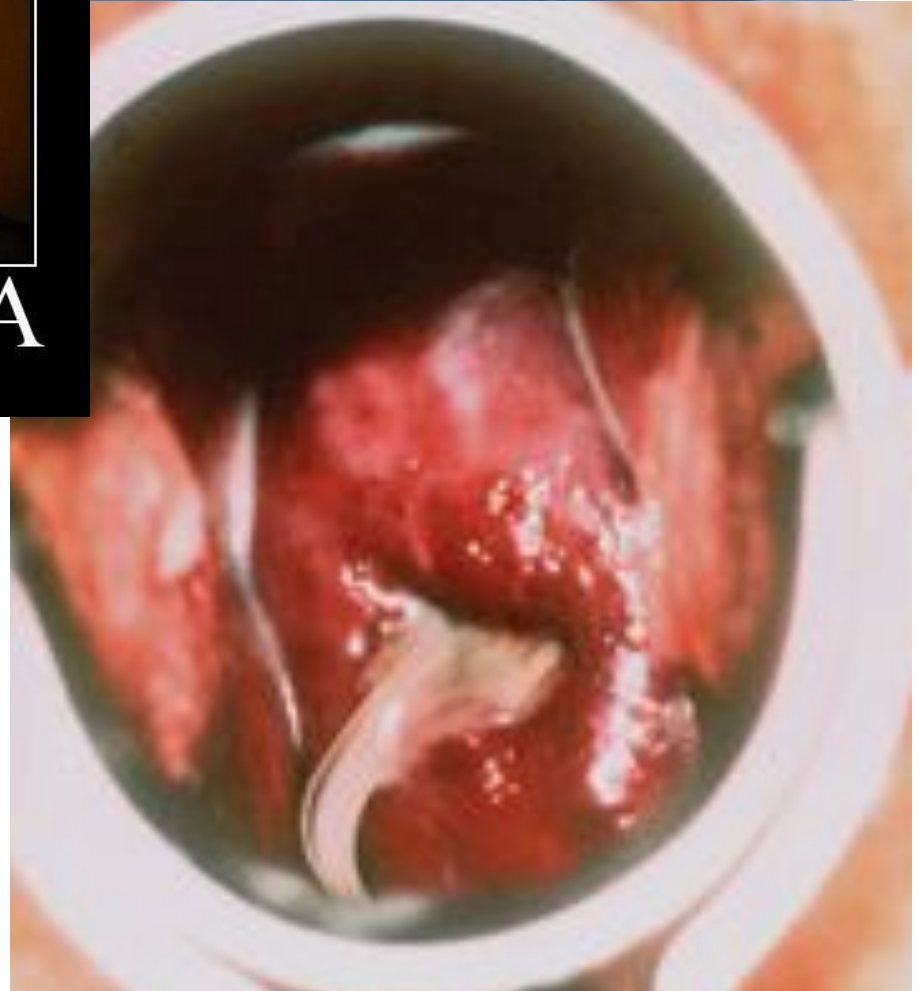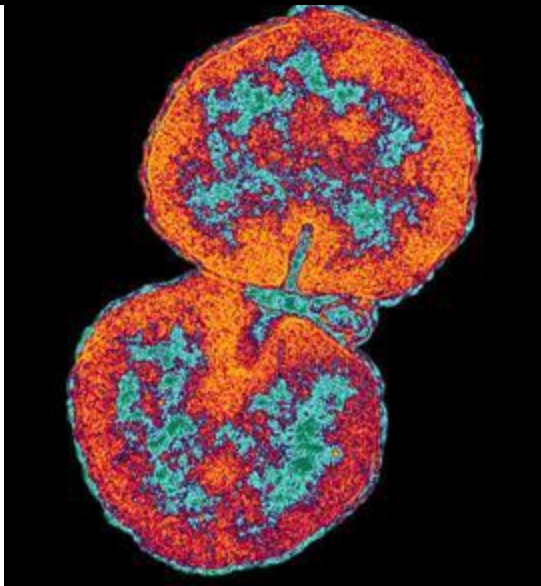


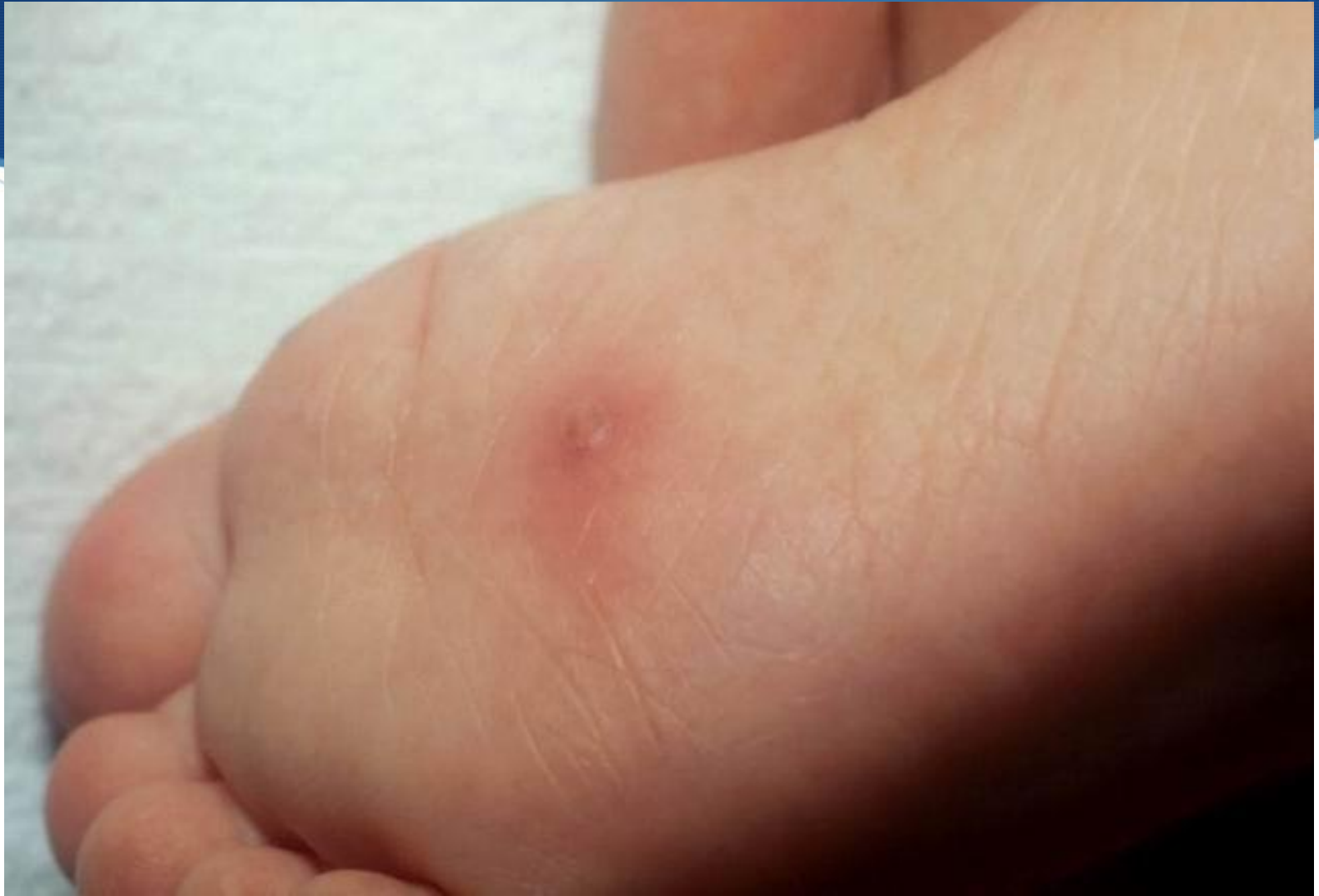* CS=congenital syphilis; P&S=primary and secondary syphilis.

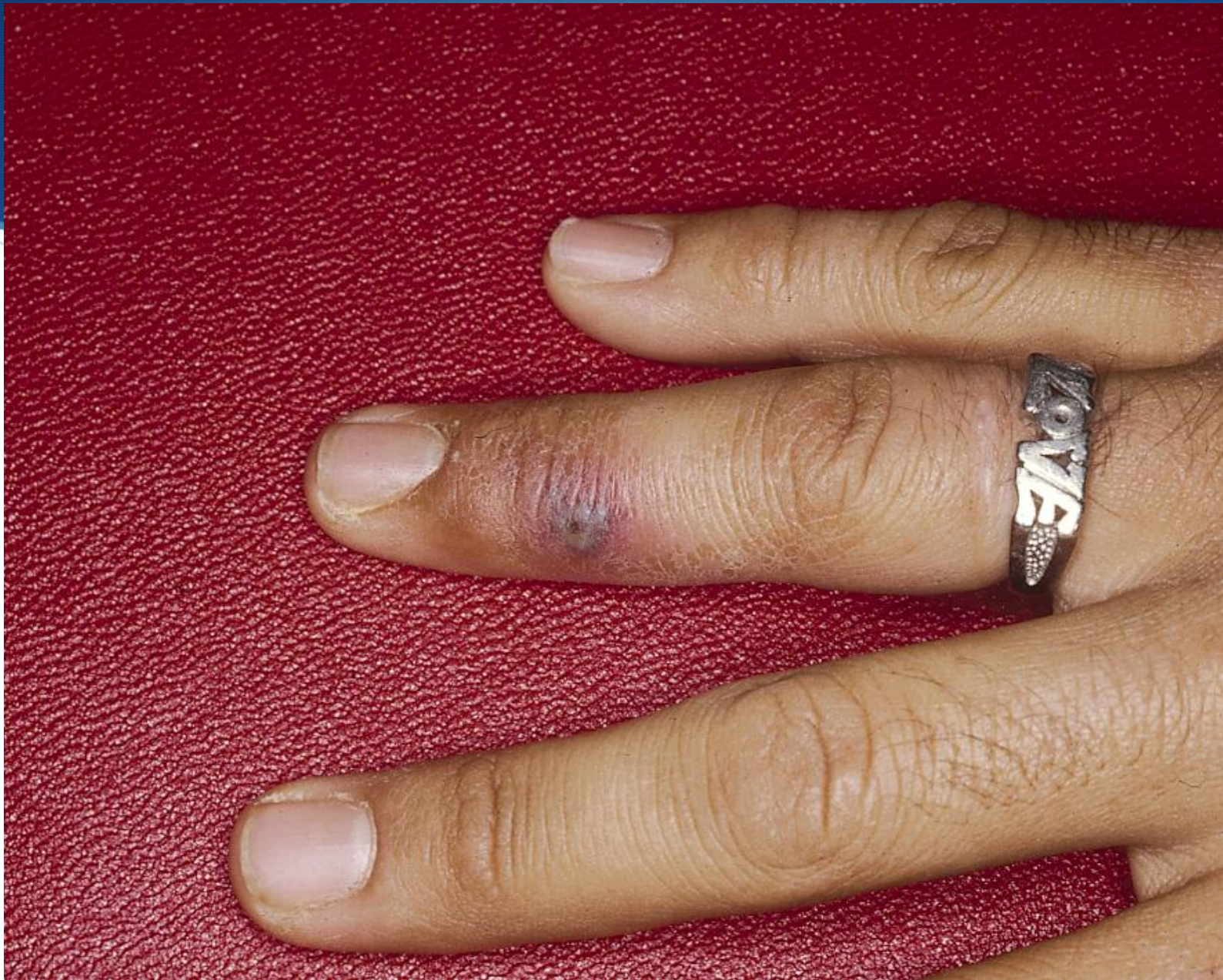

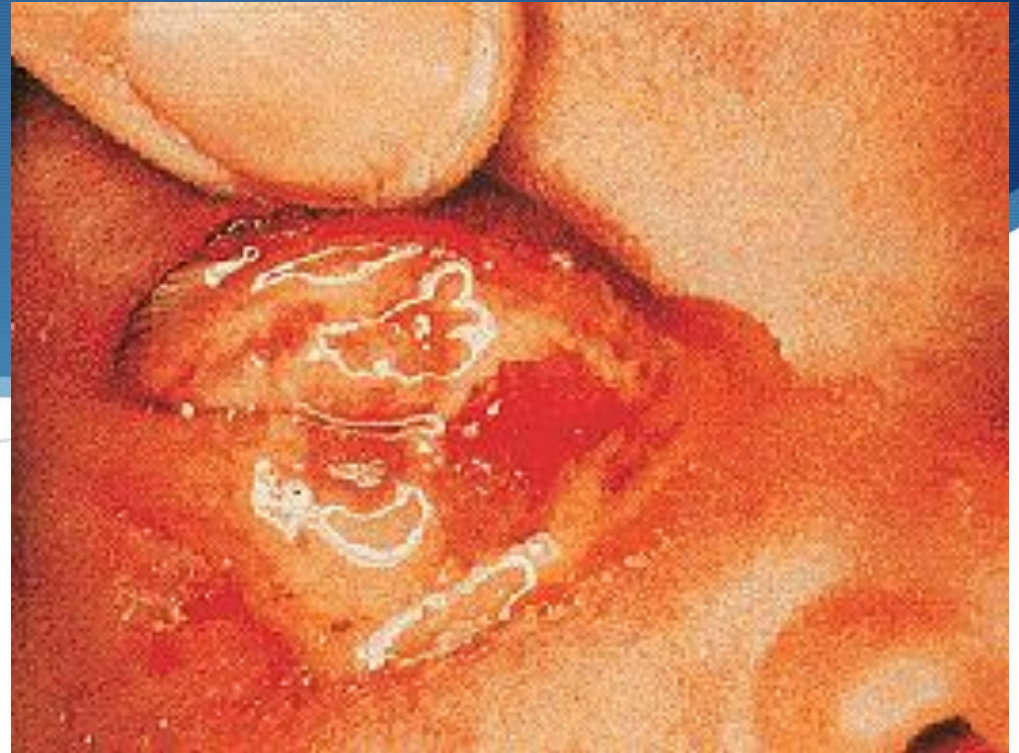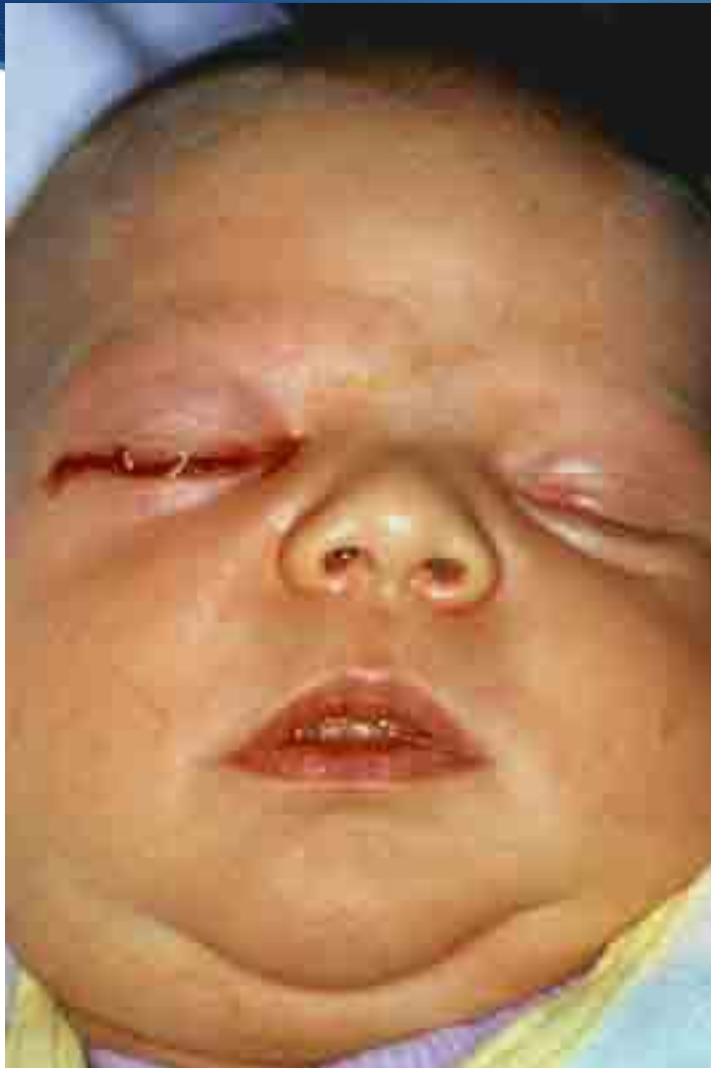GONORRHEA

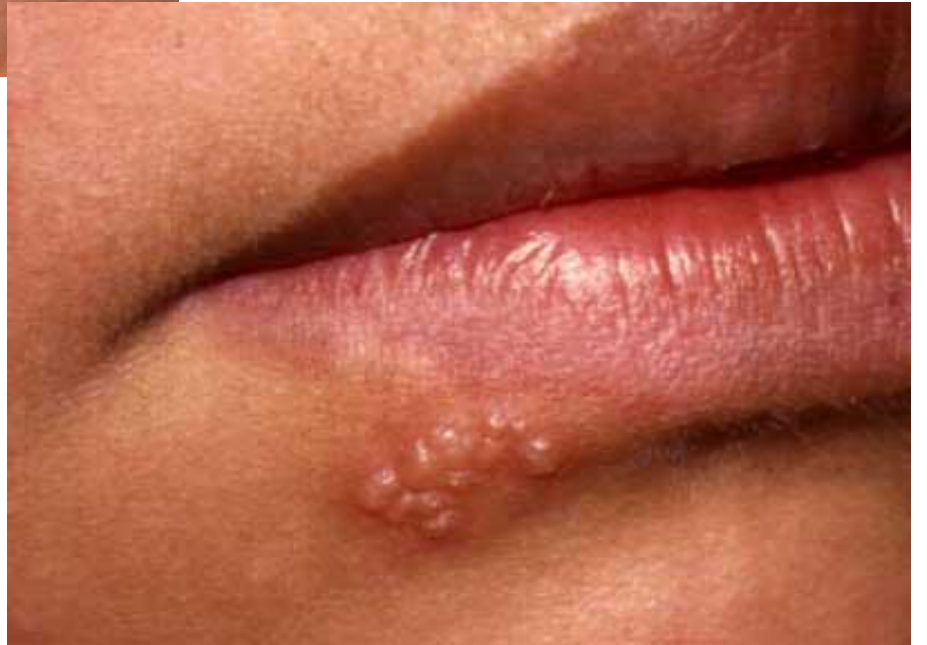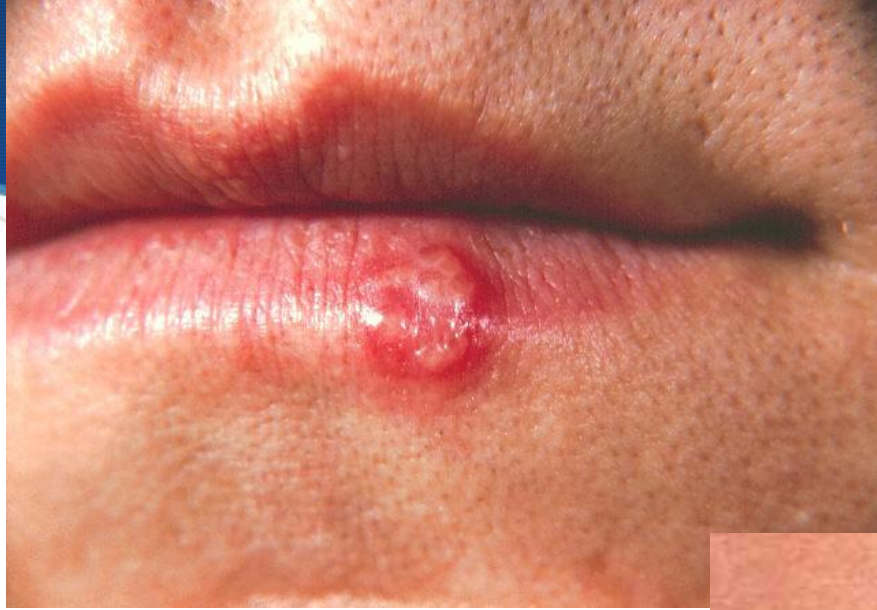Making it burn when you pee



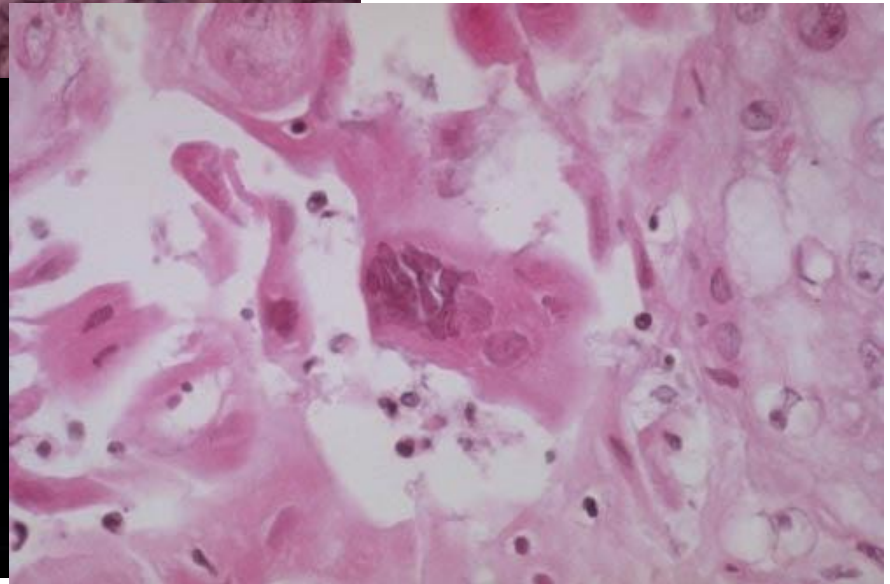
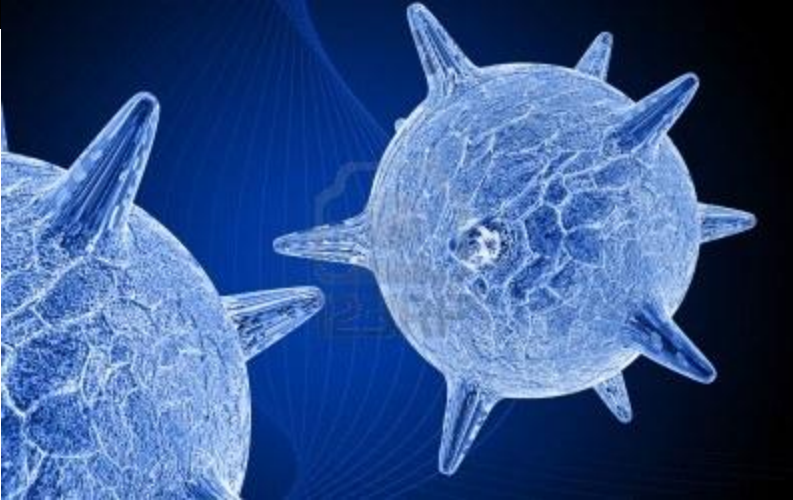
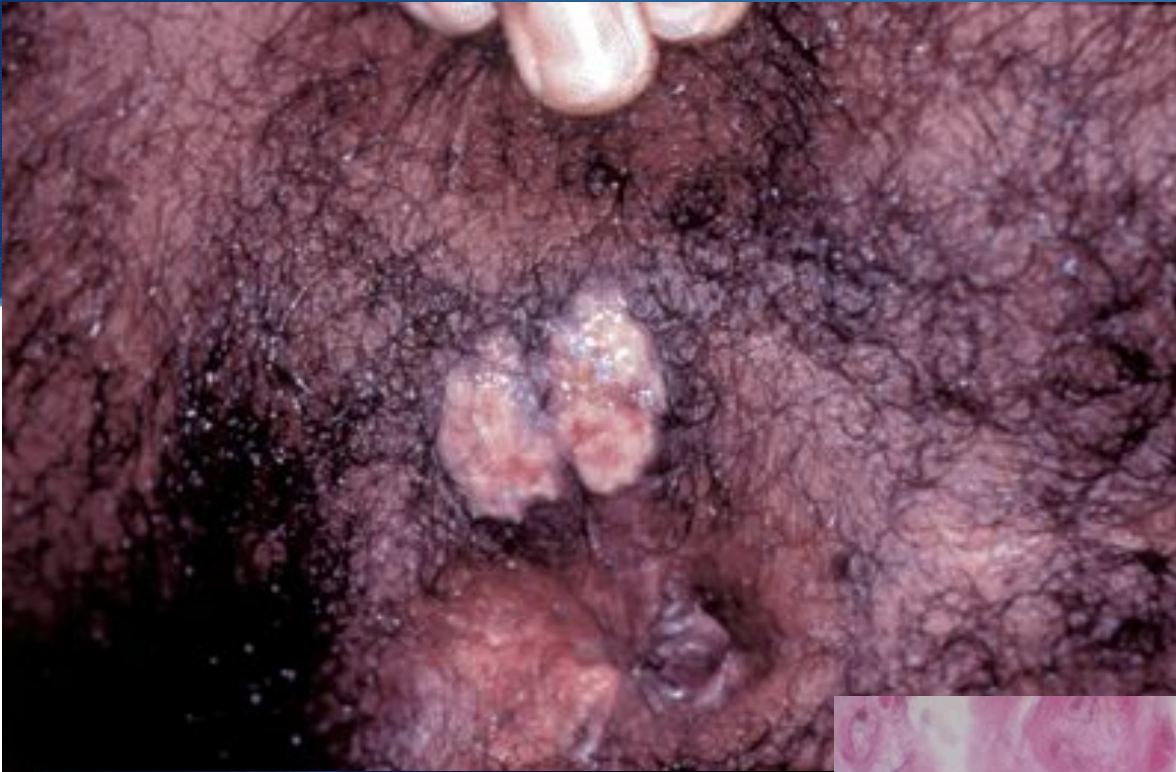

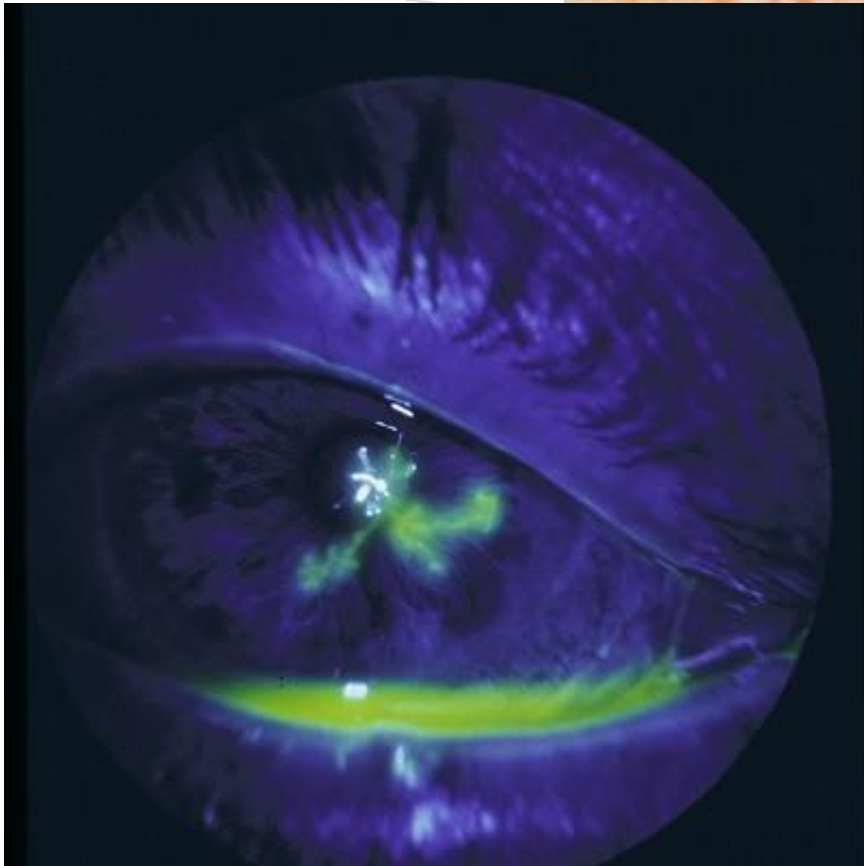

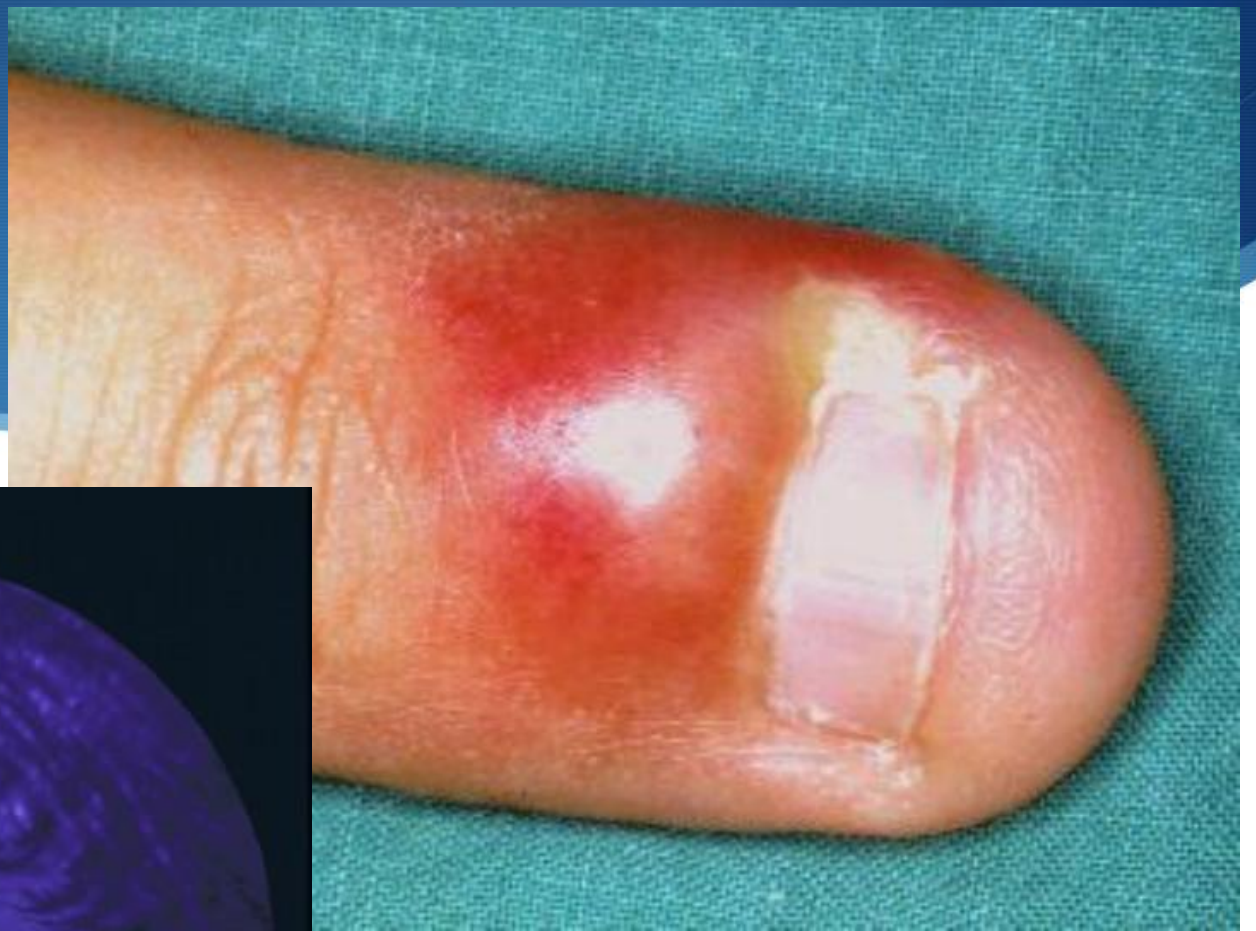


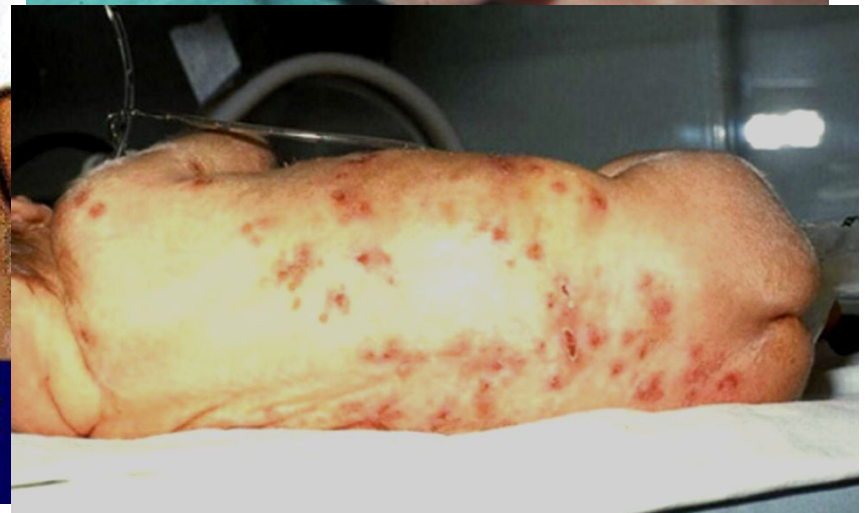
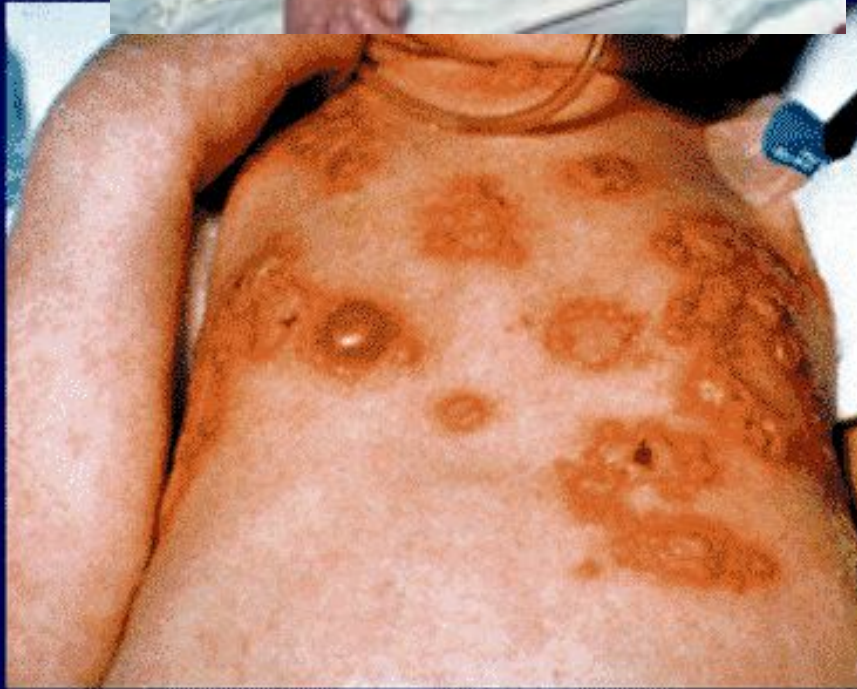
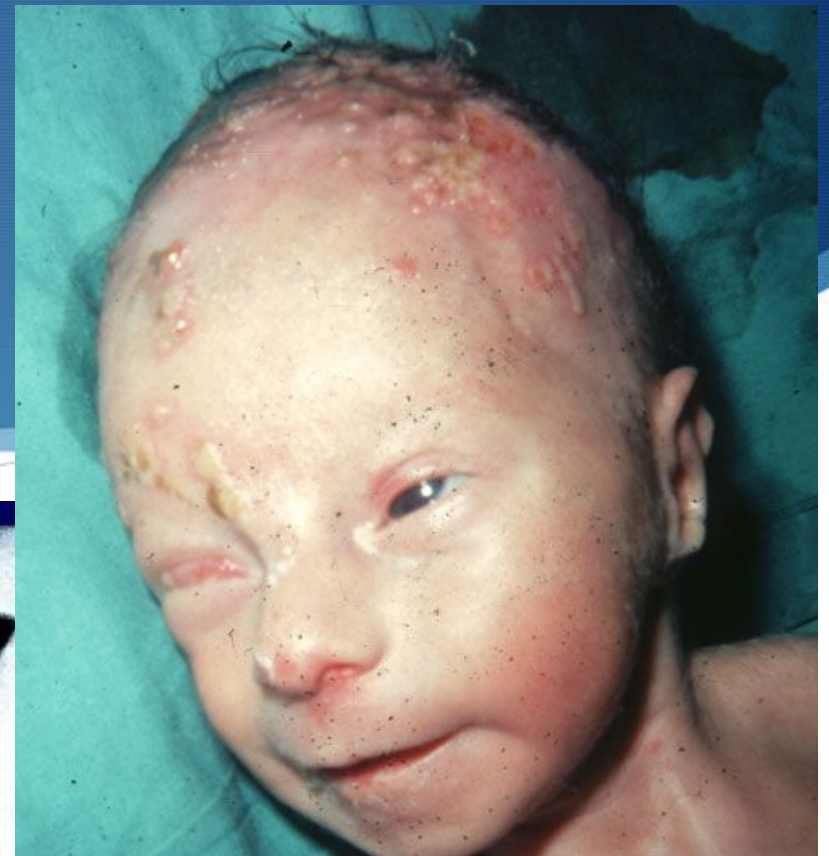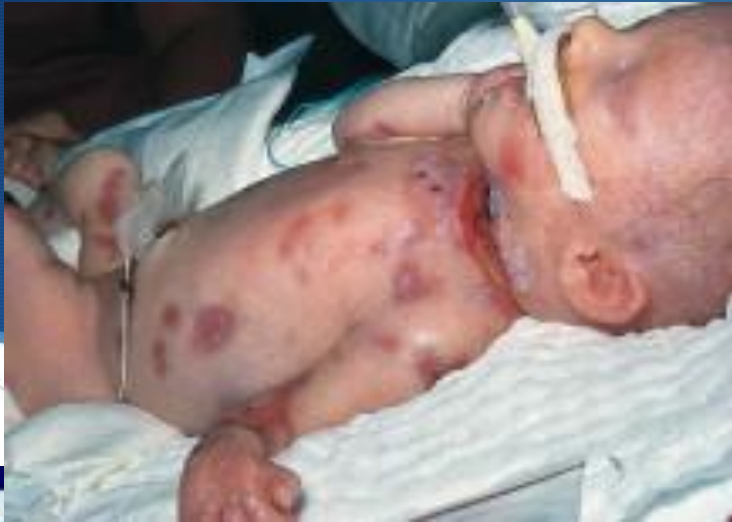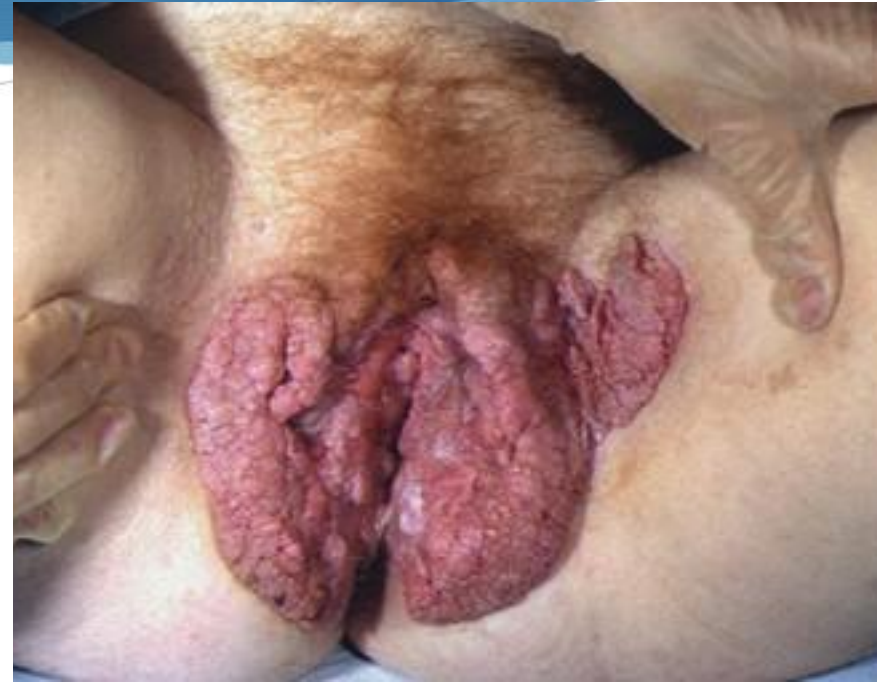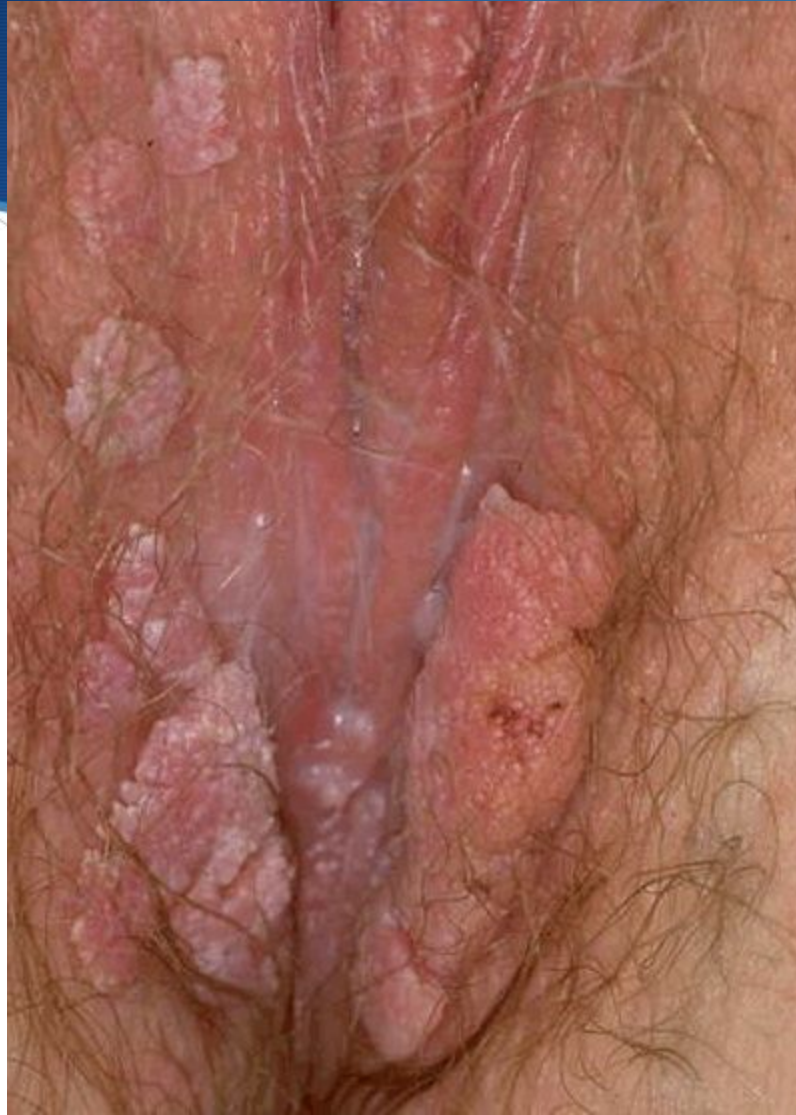Herpes Simplex Virus





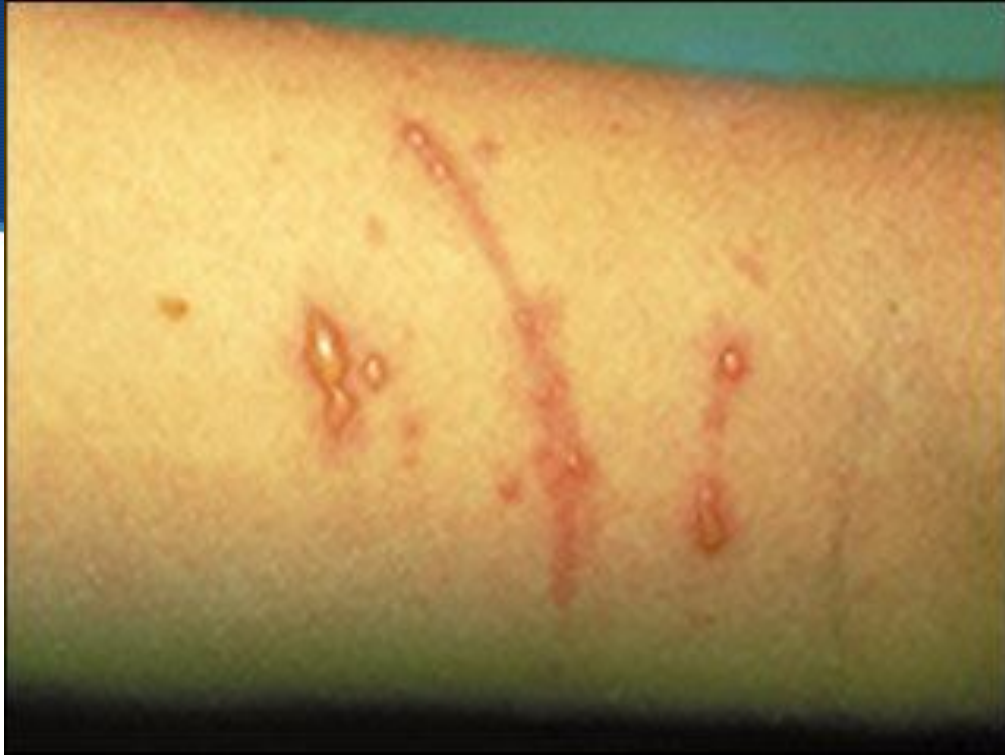

Most newborns infected with HSV are delivered to women who have asymptomatic or unrecognized infections.





Dermatologic Conditions in Obstetrics and Gynecology

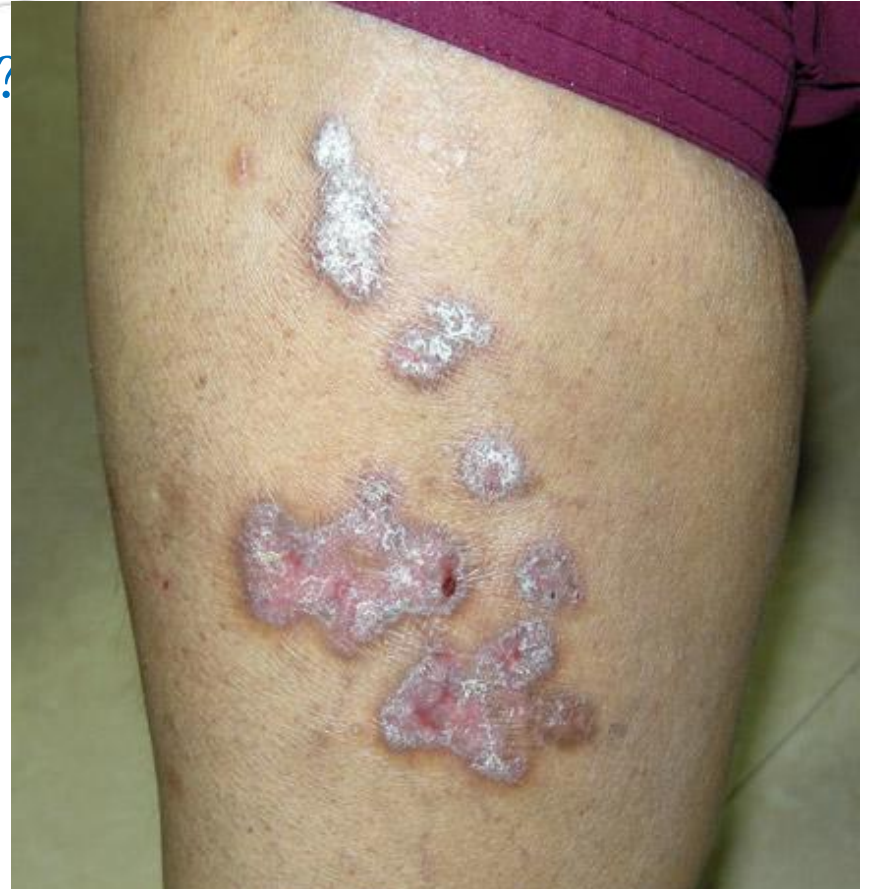

PPPPP

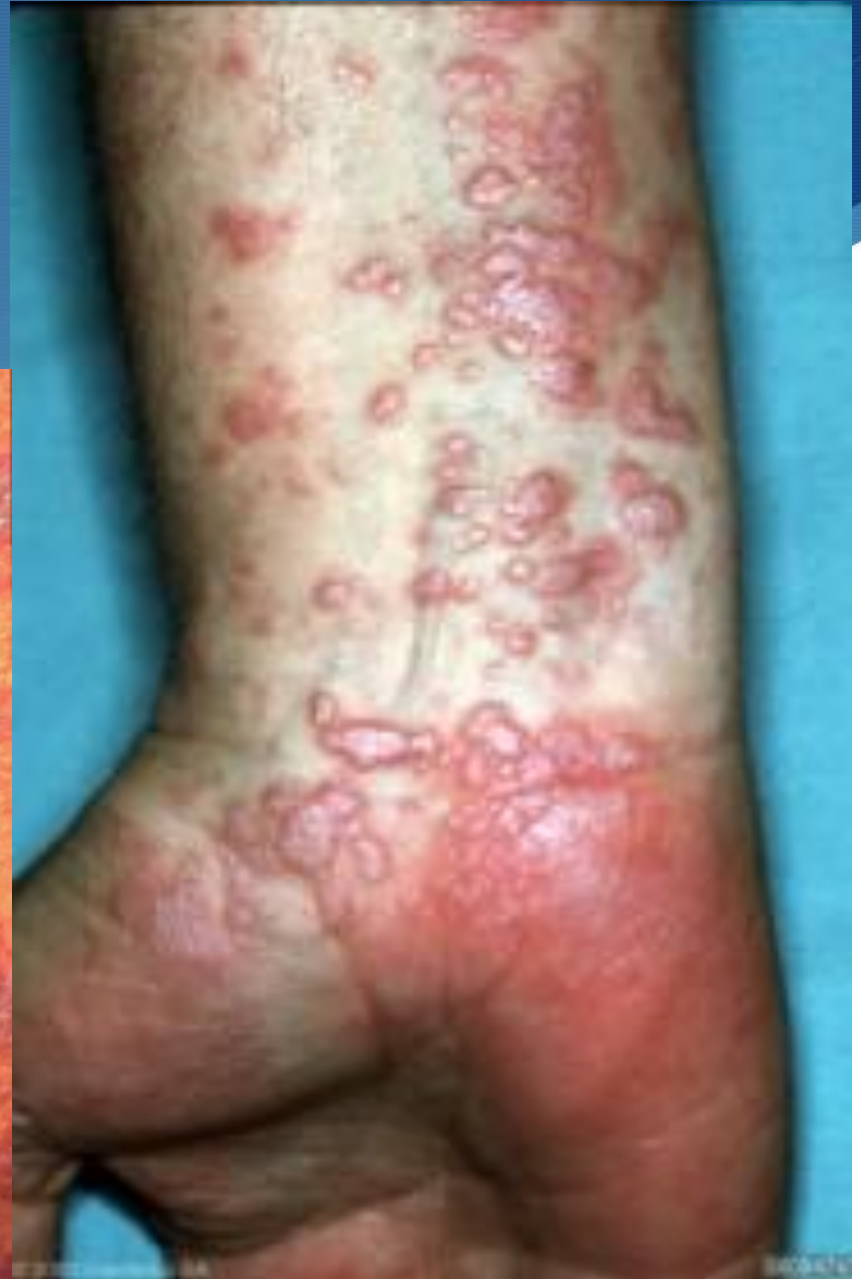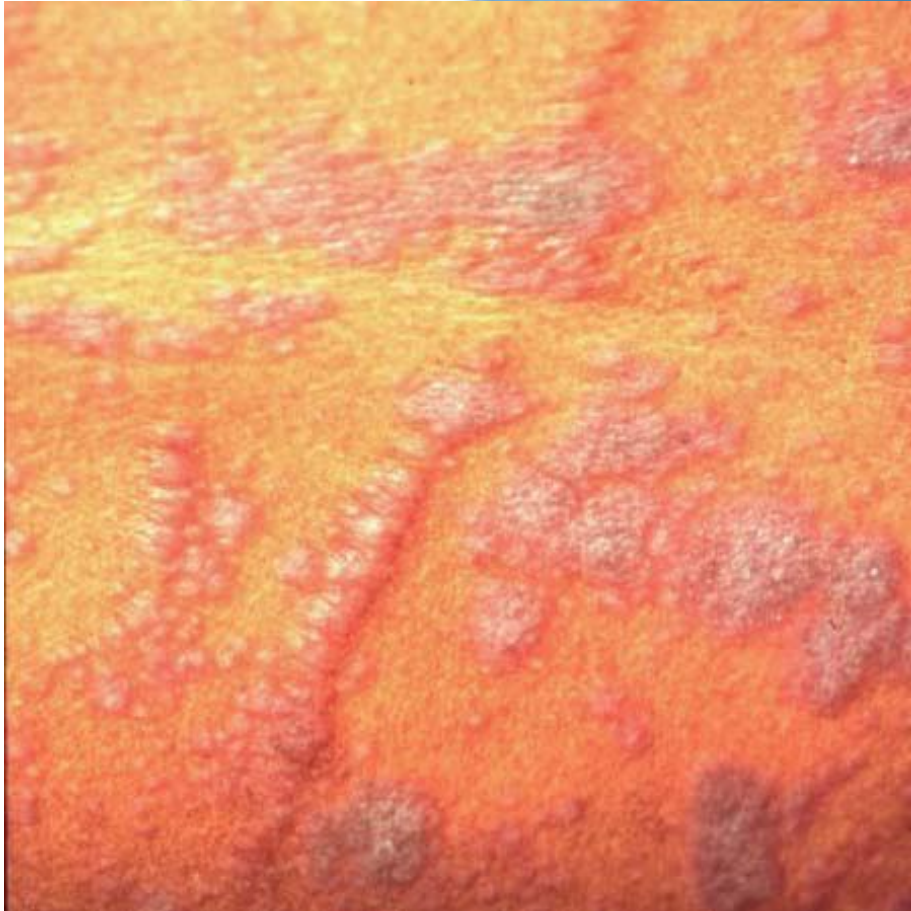💧 What has more P's than PUPPP?

💧 The 5 Ps of lichen planus:

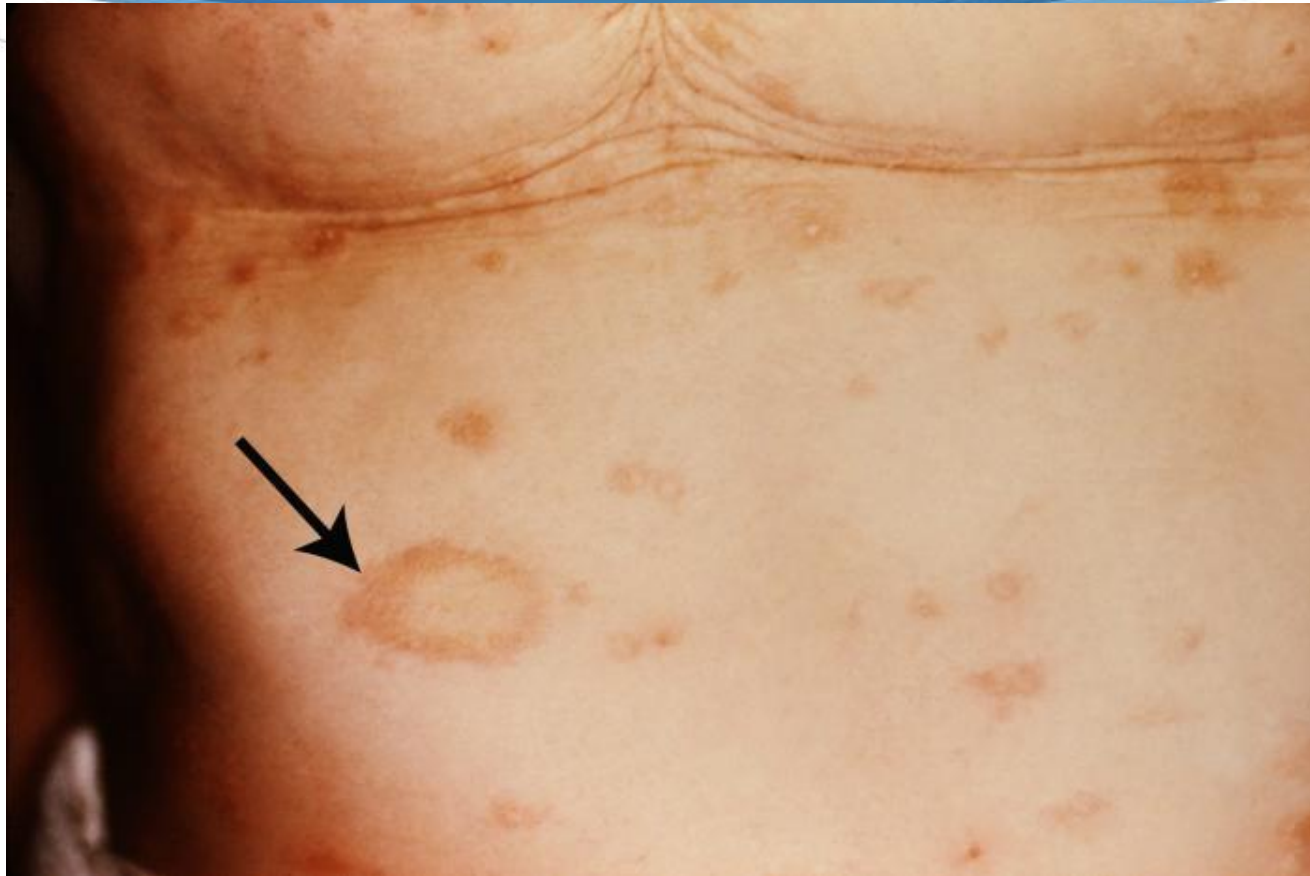- 💧 planar
- 💧 polygonal
- 💧 pruritic
- 💧 purple
- 💧 papular

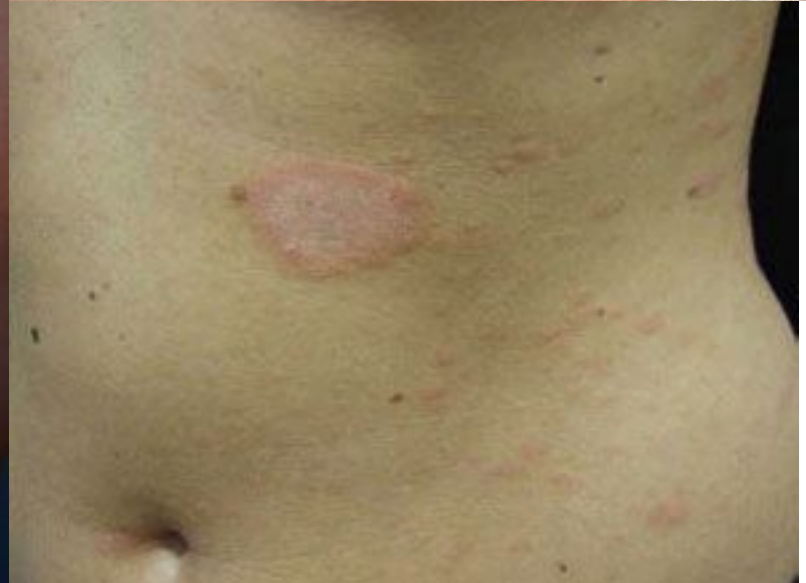
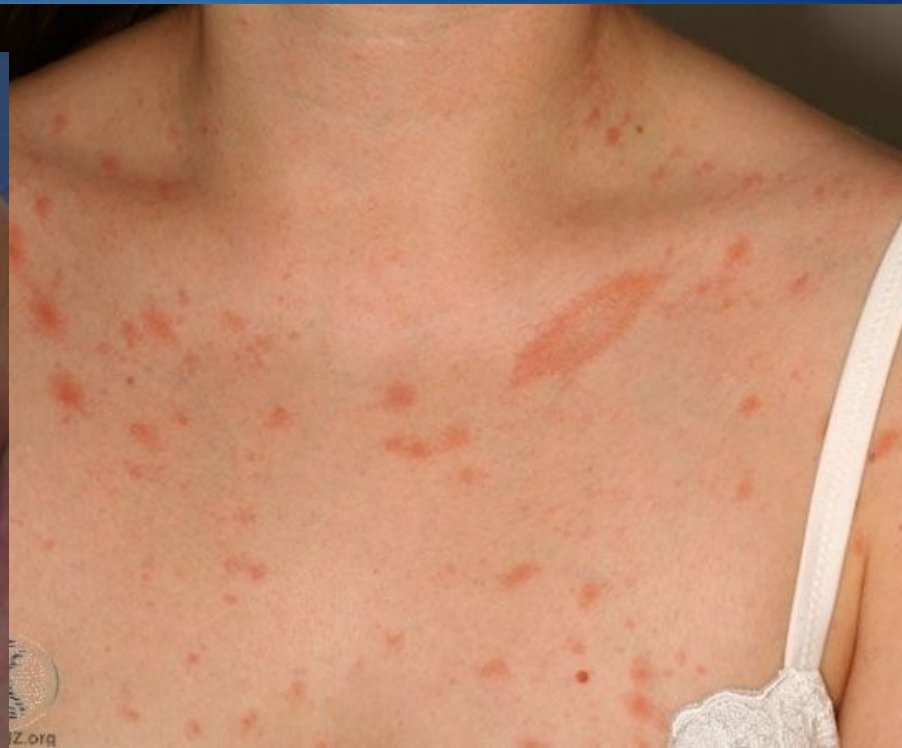
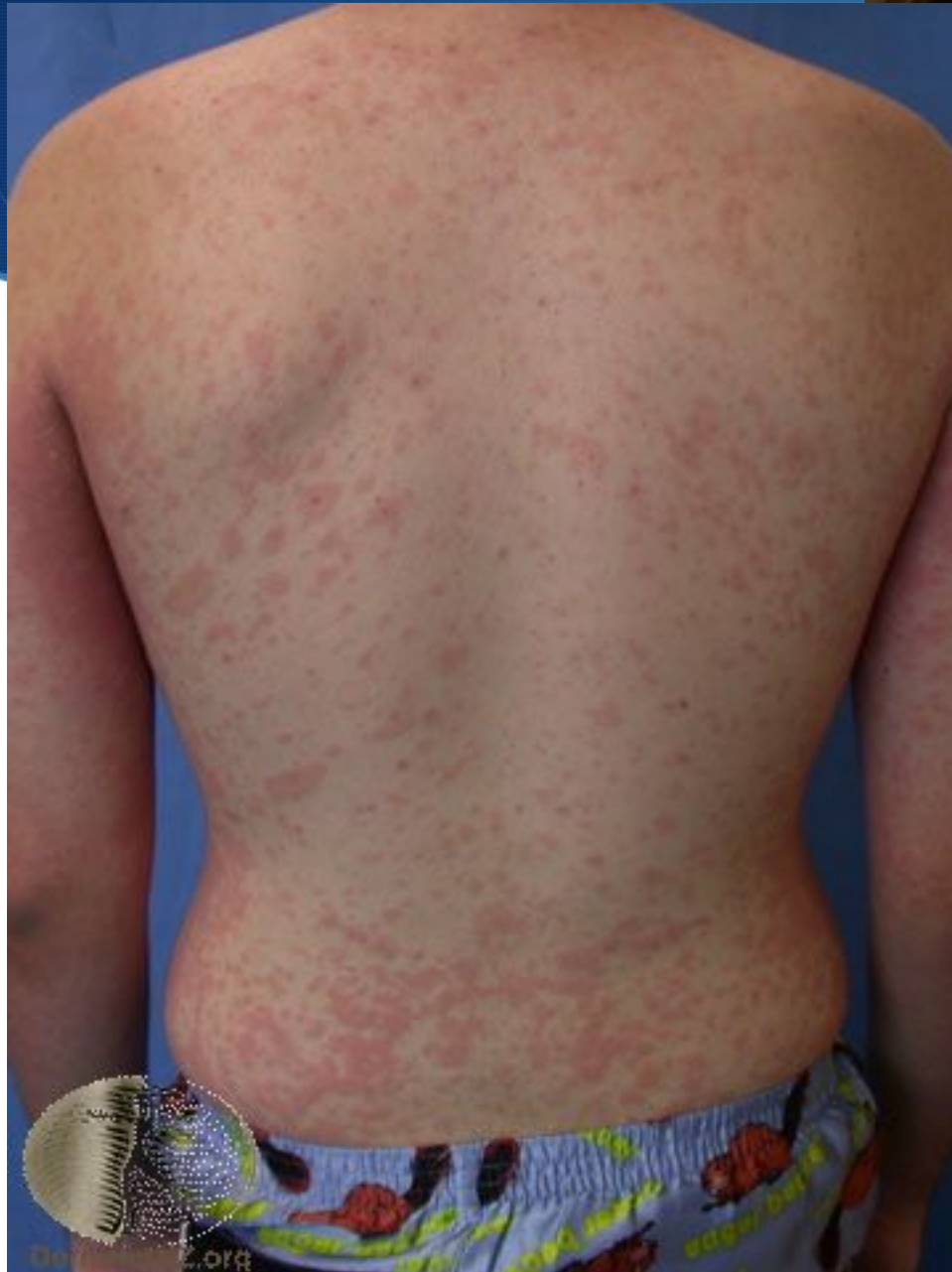Lichen Planus

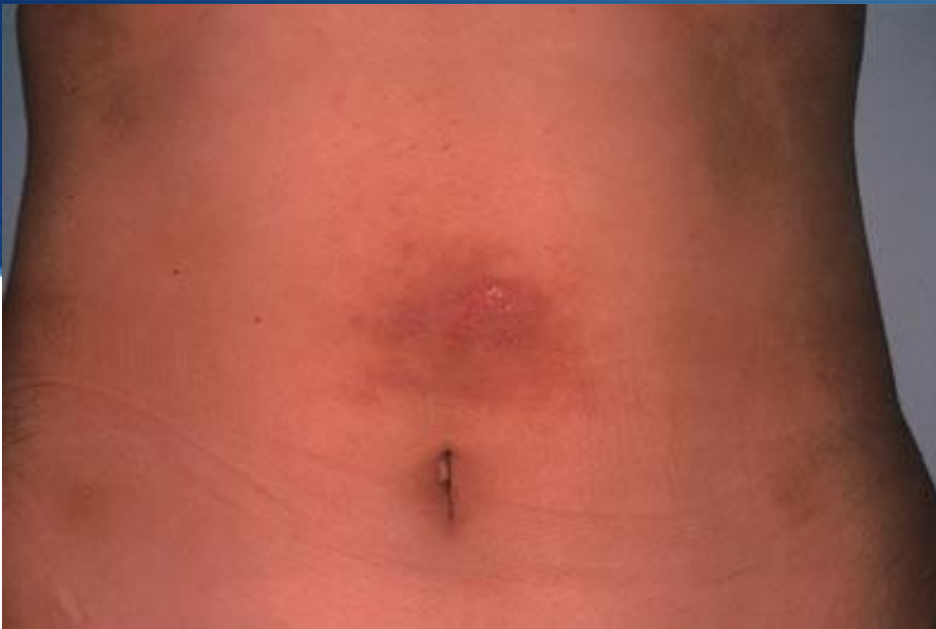

Pityriasis Rosea

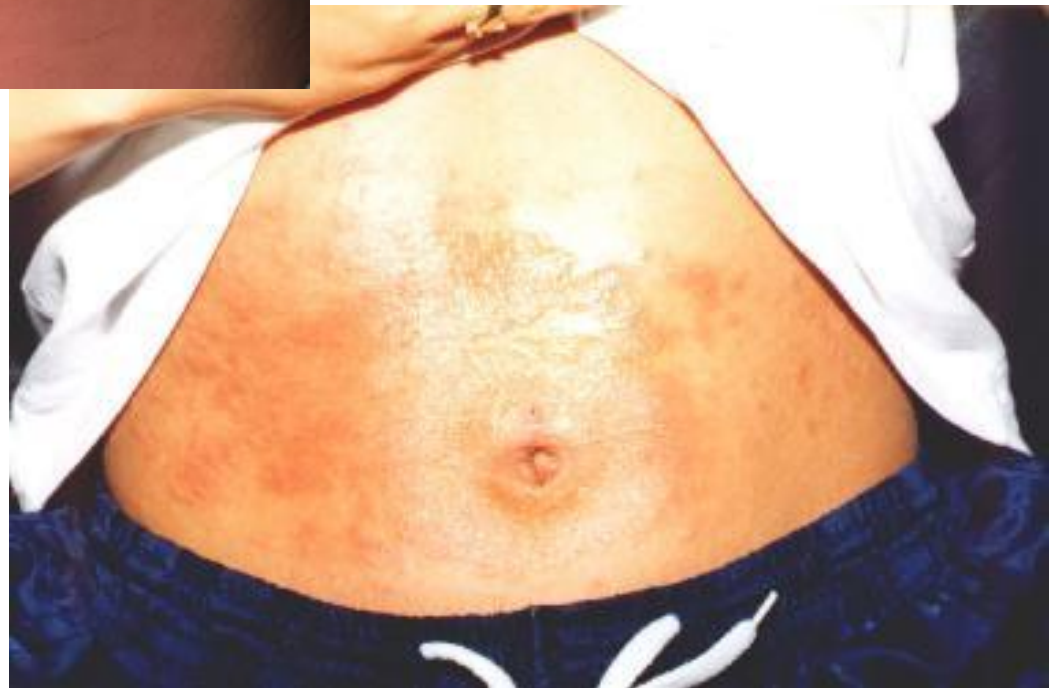


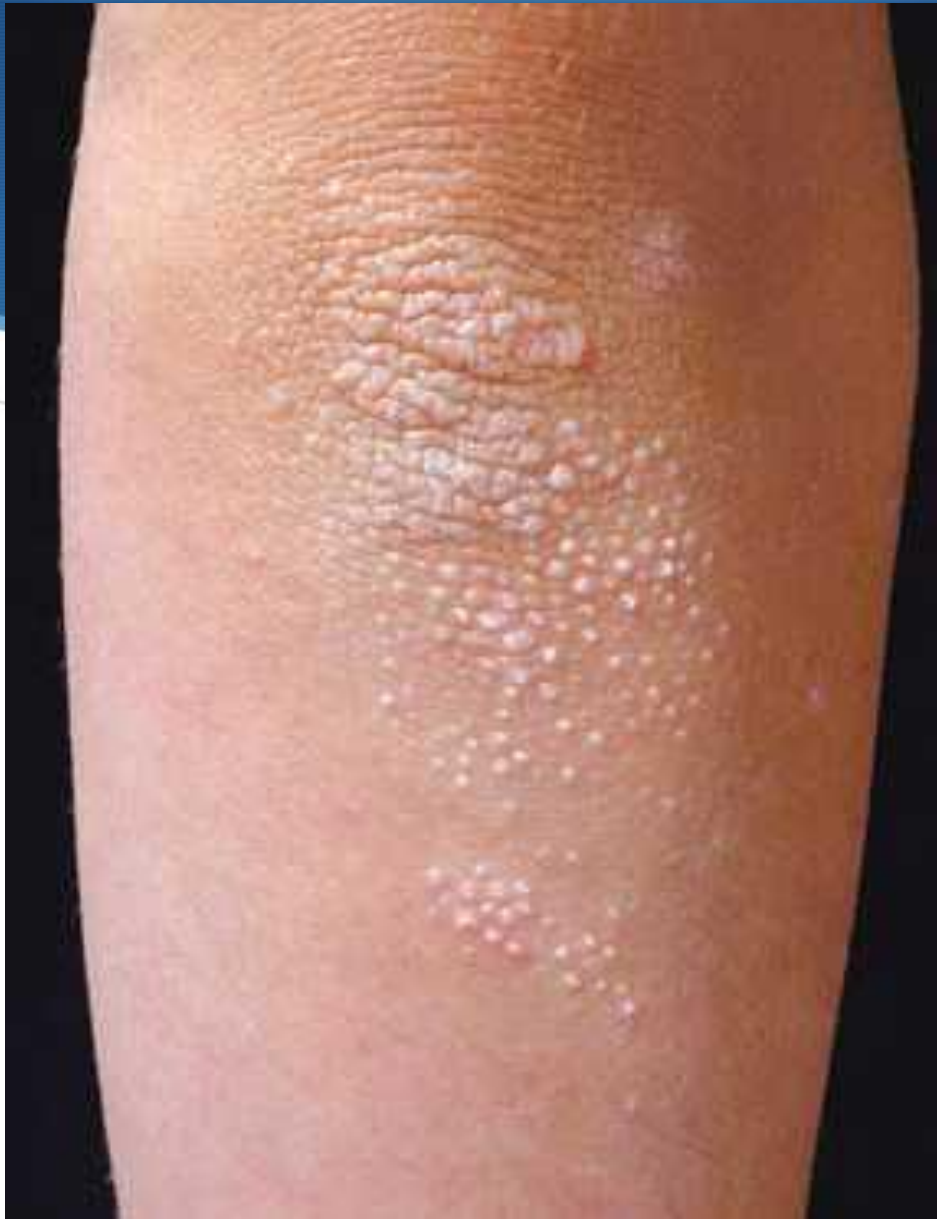
All that glitters.....

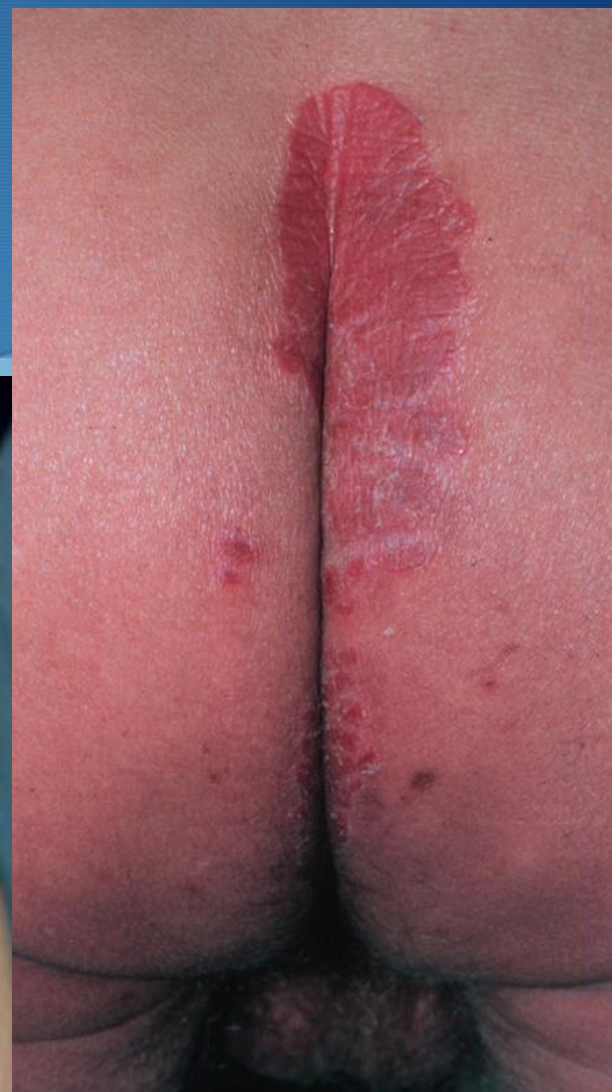
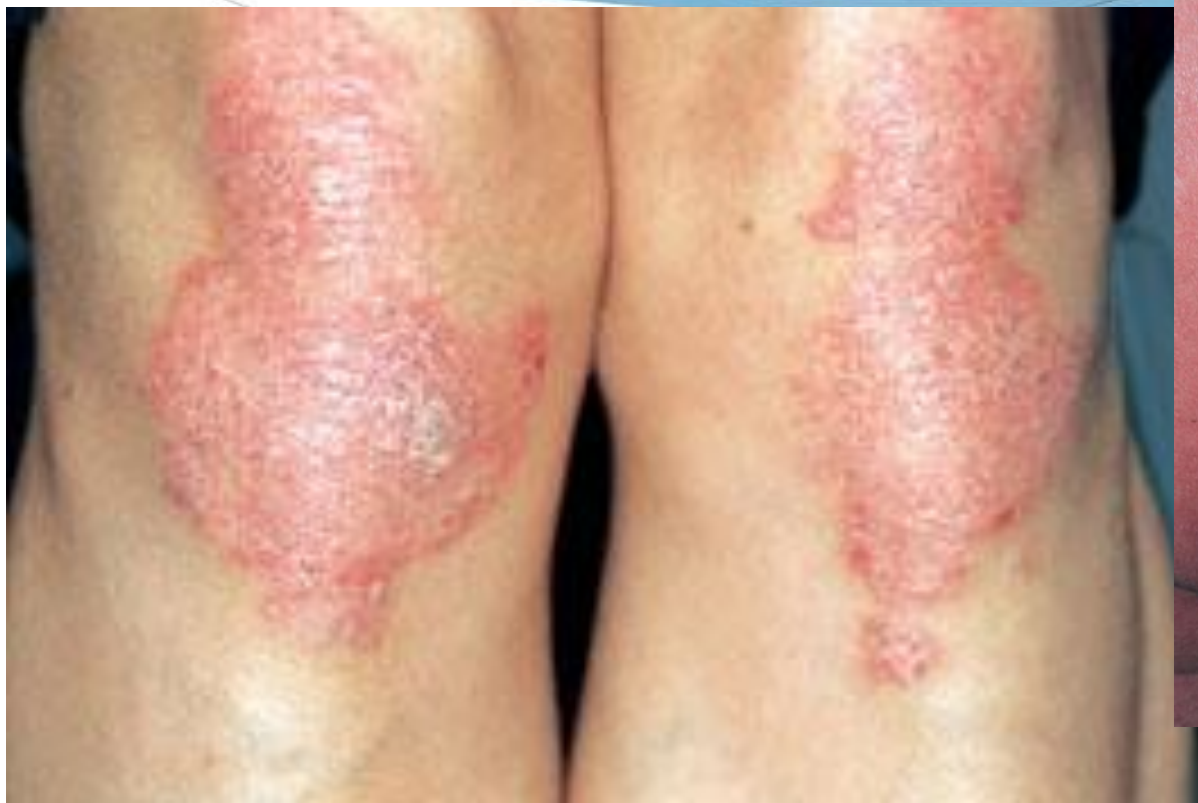
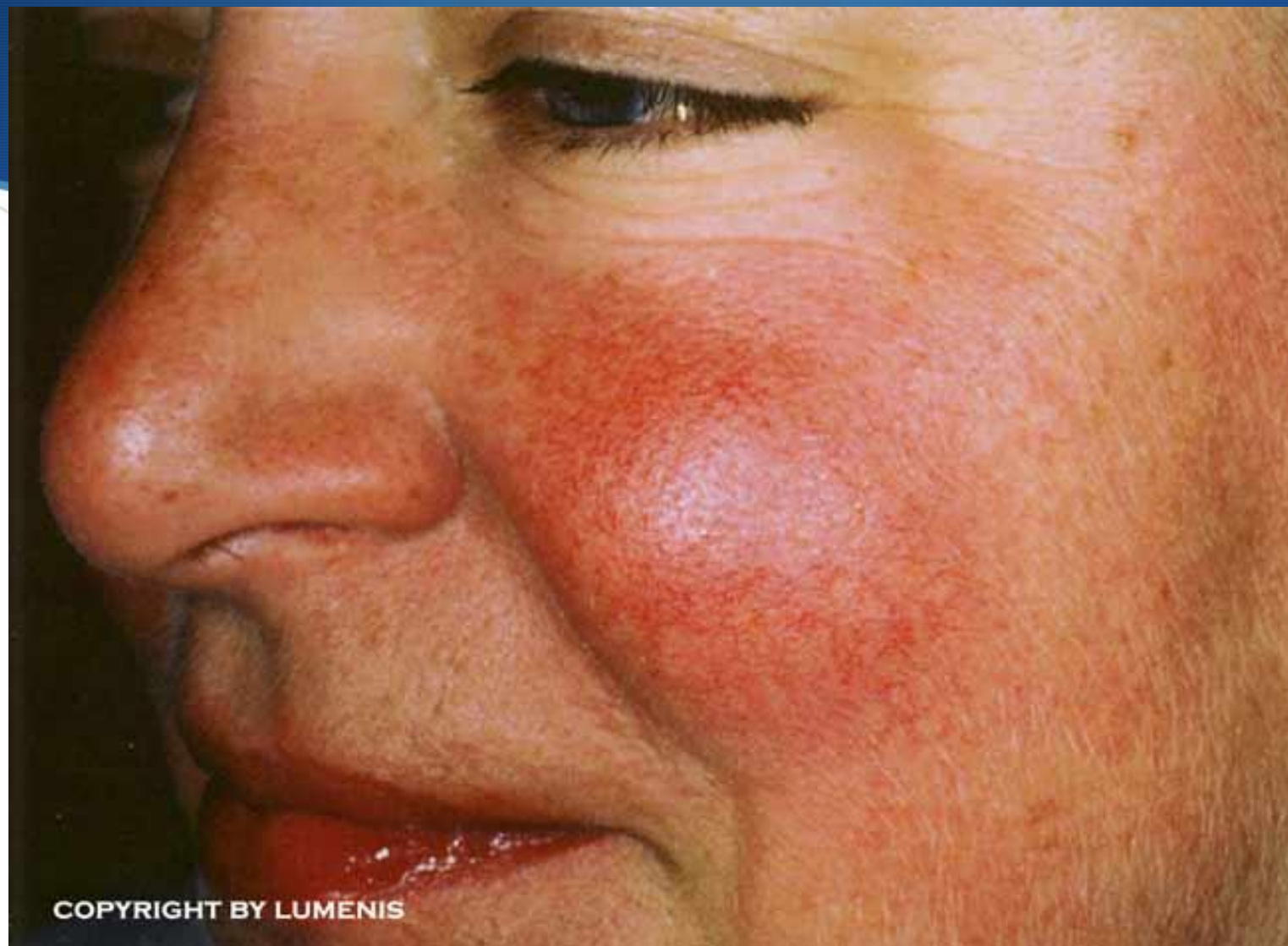.... might be
nickel and
not gold.



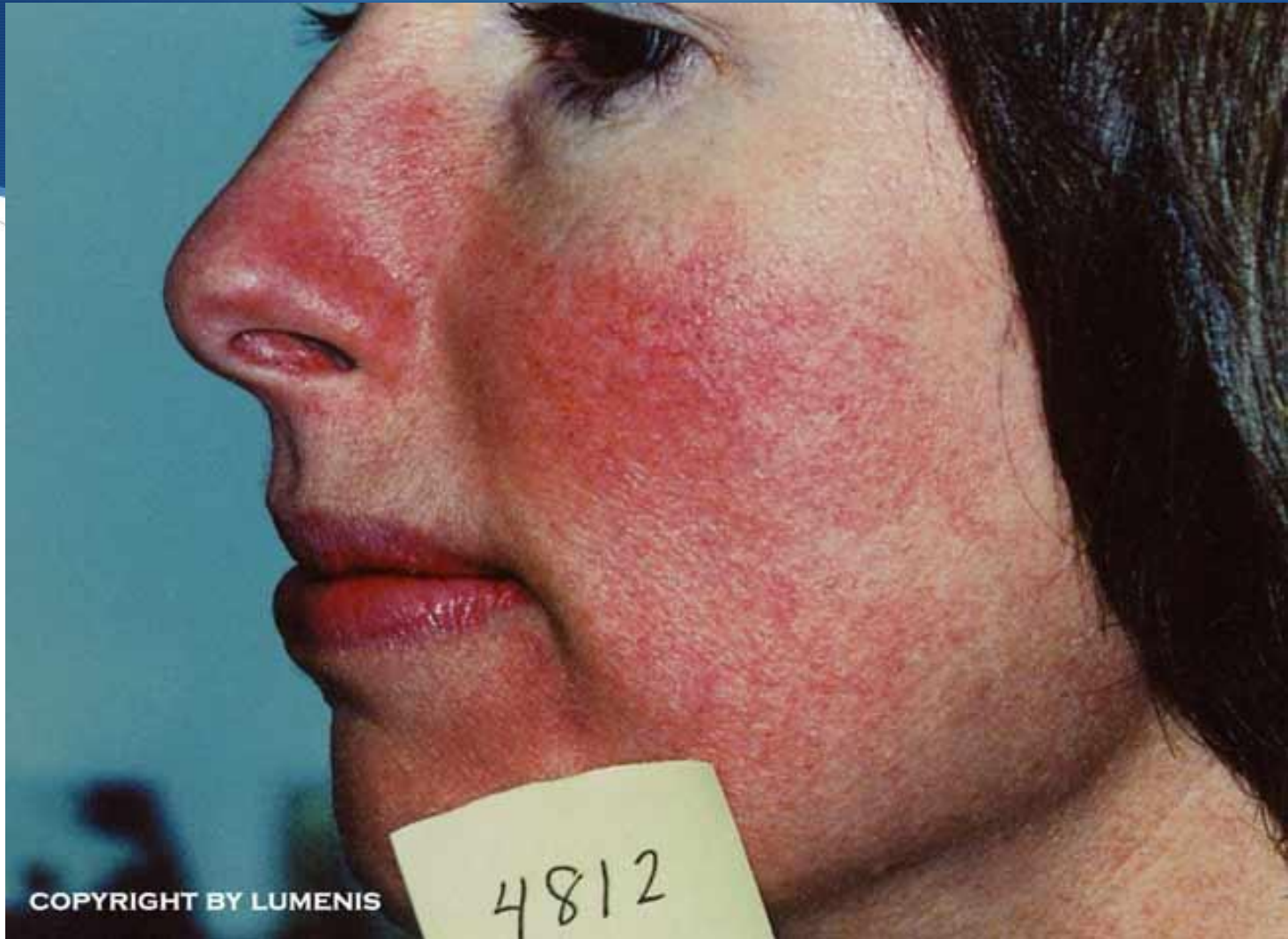

Psoriasis



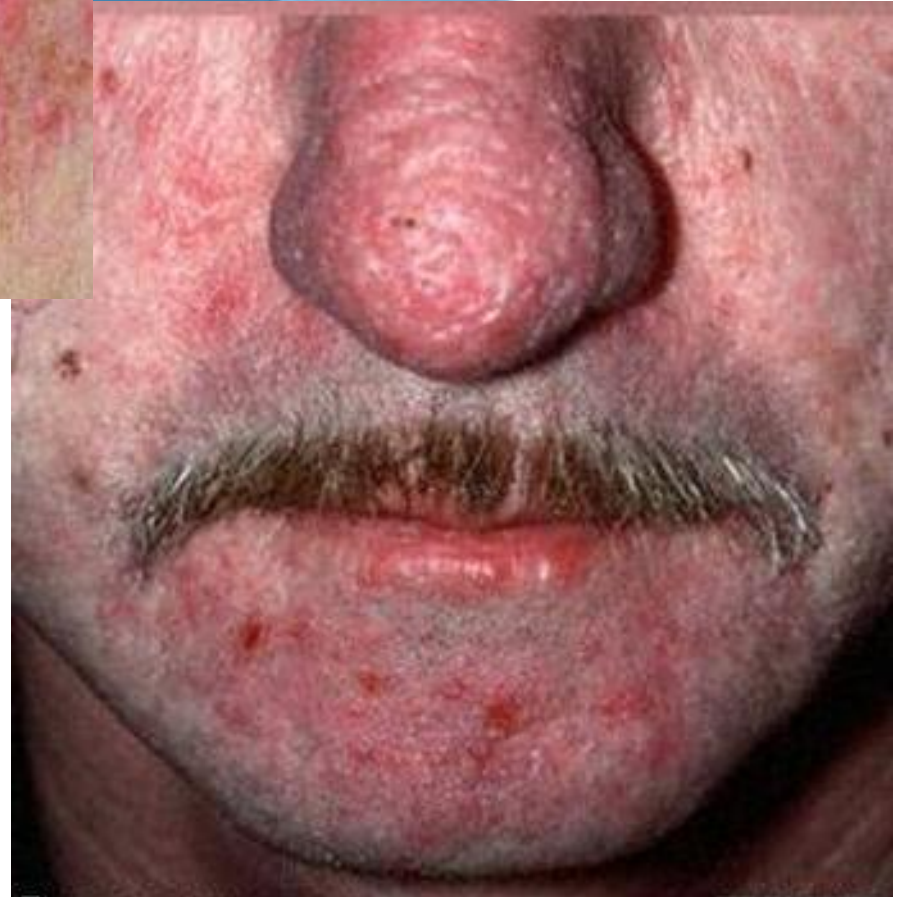
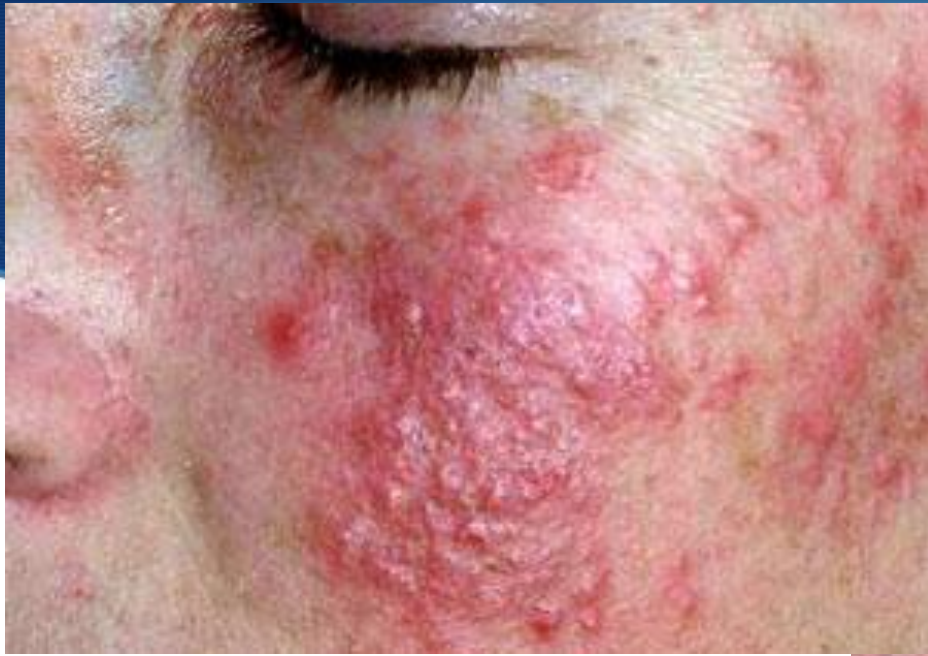

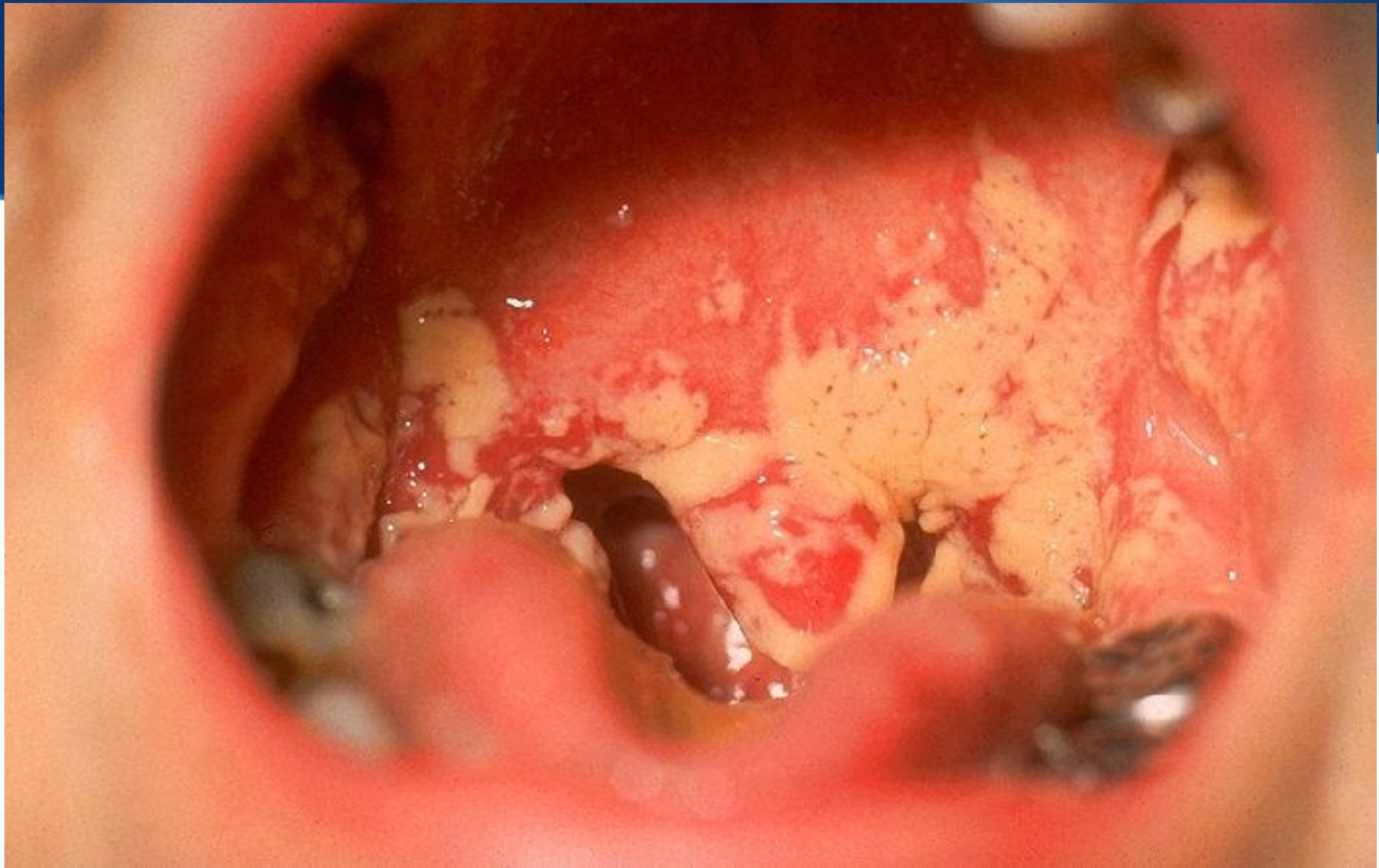COPYRIGHT BY LUMENIS



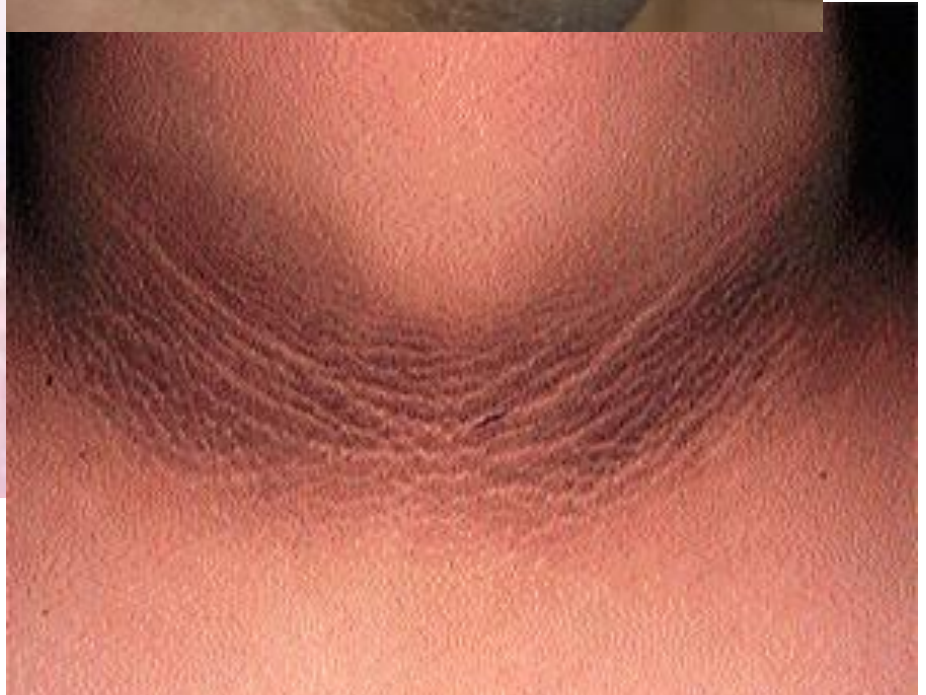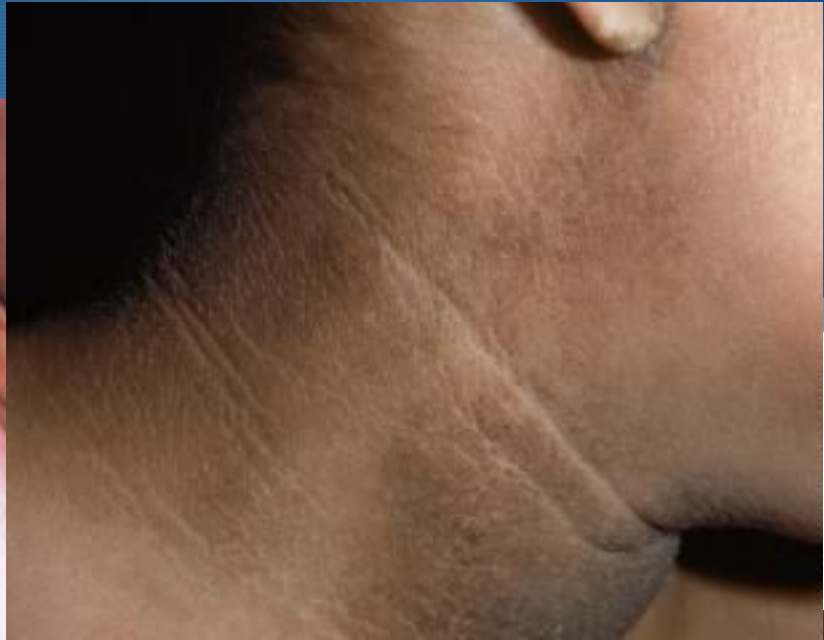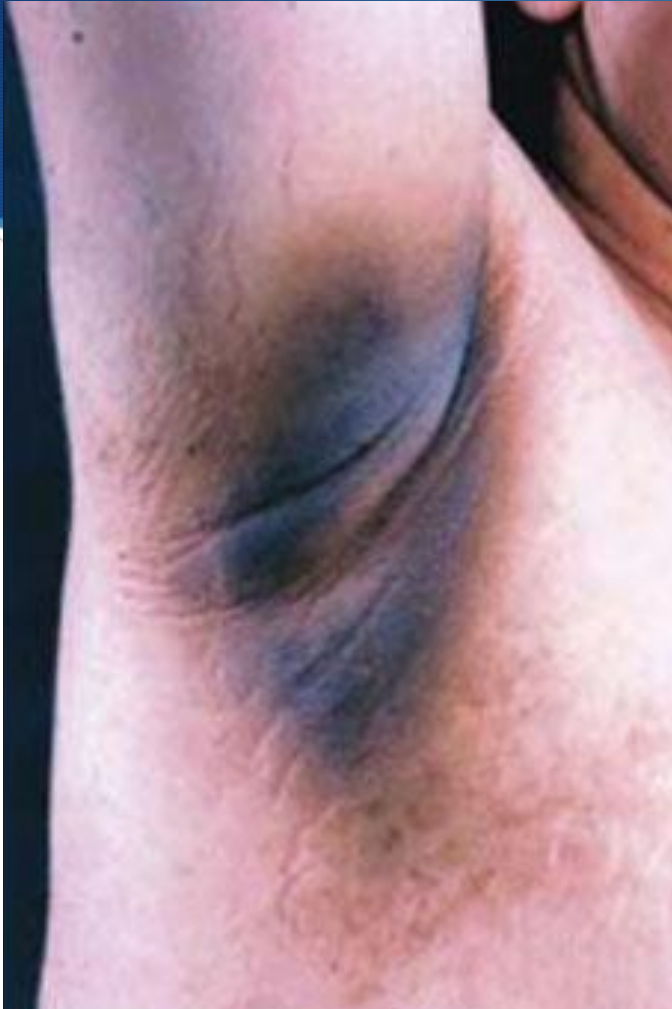COPYRIGHT BY LUMENIS

4812





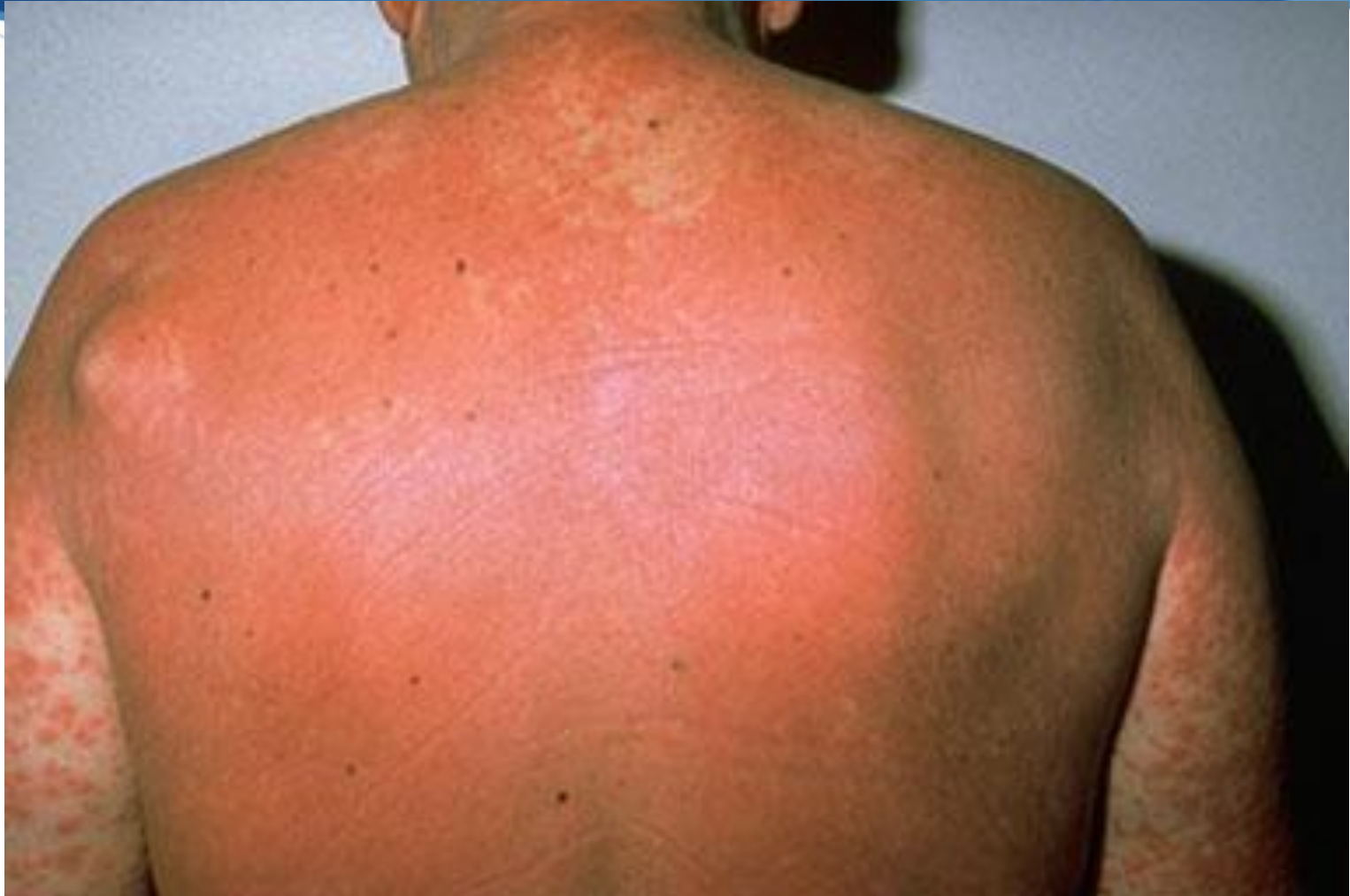Candida albicans

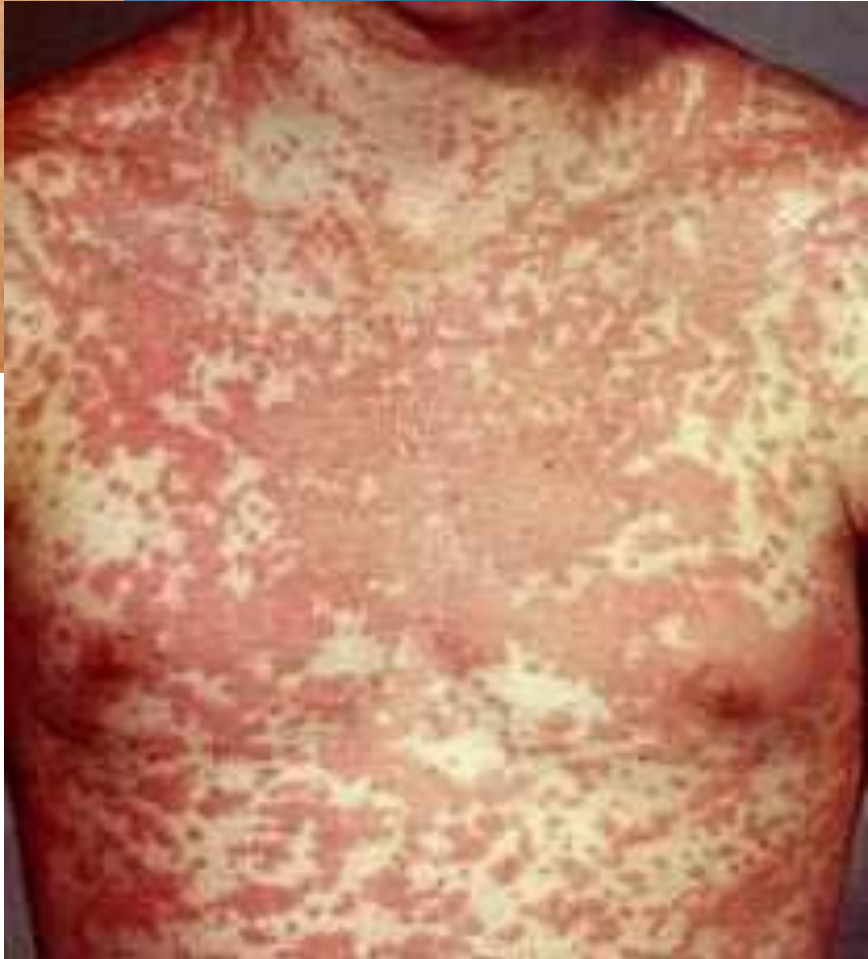
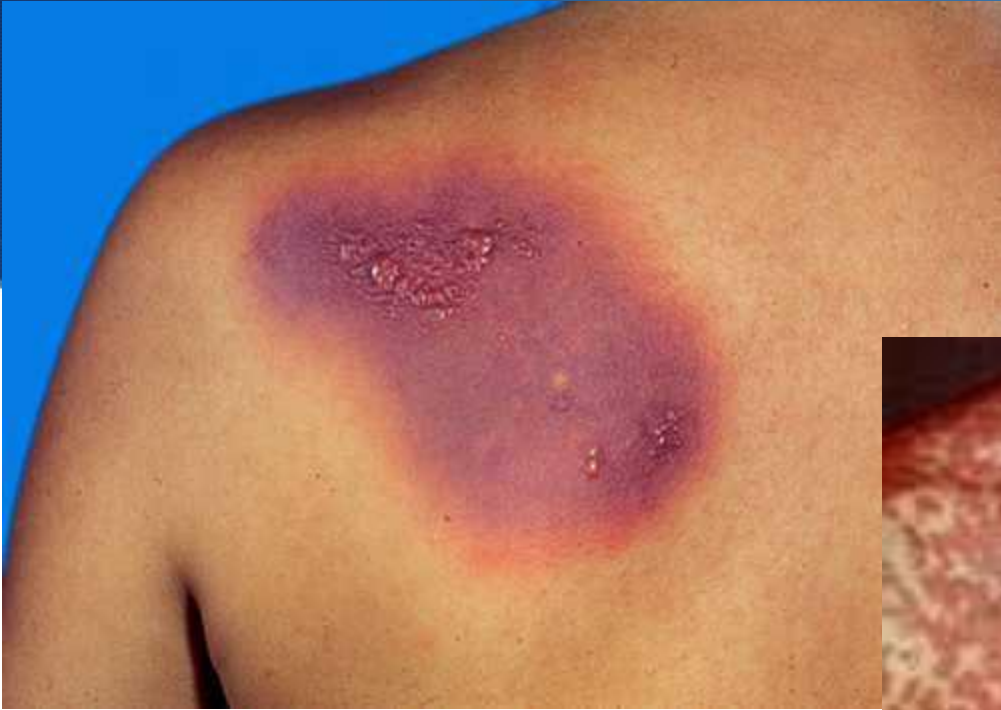
Acanthosis Nigricans

- 💧 Dark, thick, velvety skin in body folds and creases
- 💧 Obesity is a common cause
- 💧 Found with obesity-related insulin resistance (HAIR-AN)
- 💧 Seen with human growth hormone and birth control pills
- 💧 Lymphoma or cancers of the gastrointestinal or genitourinary tracts

Drug Eruptions





Drug Eruptions

Fixed Drug Eruptions

Trimethoprim-sulphamethoxazole

Tetracycline

Paracetamol

Aspirin

Exanthems

Ampicillin and Penicillin

Phenylbutazone

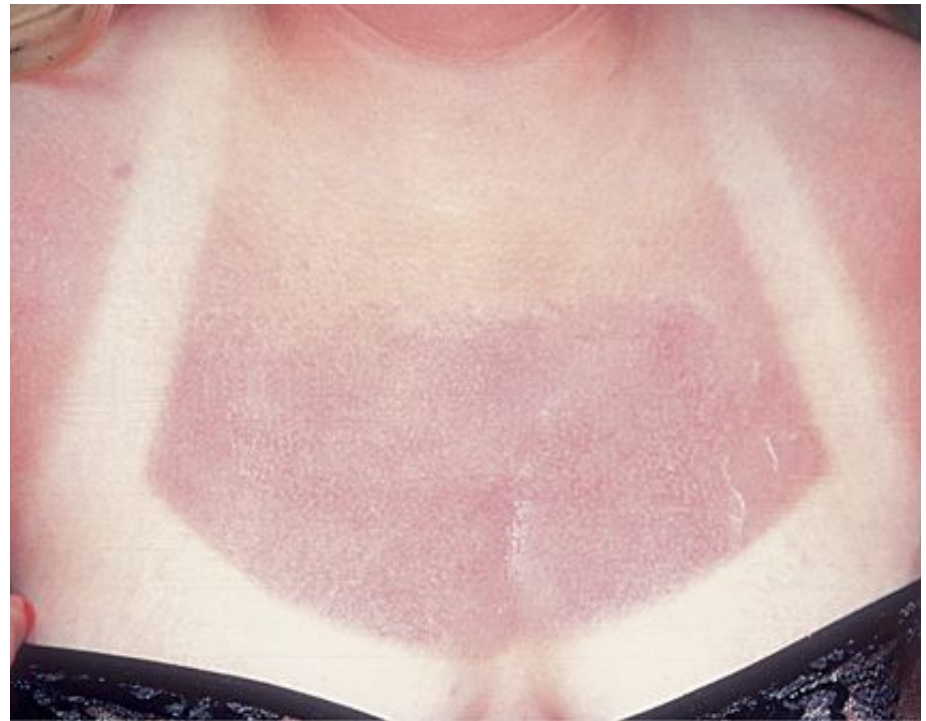Sulphonamides

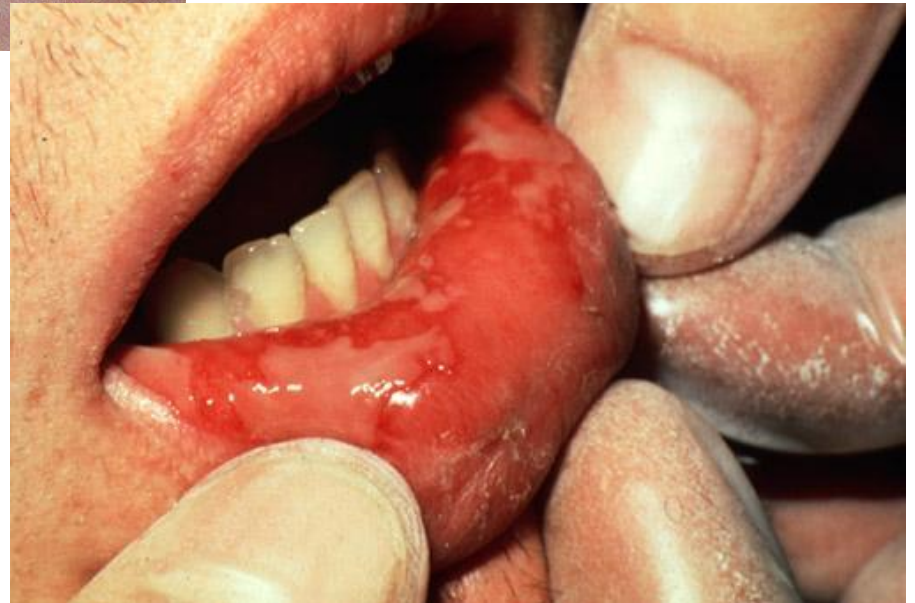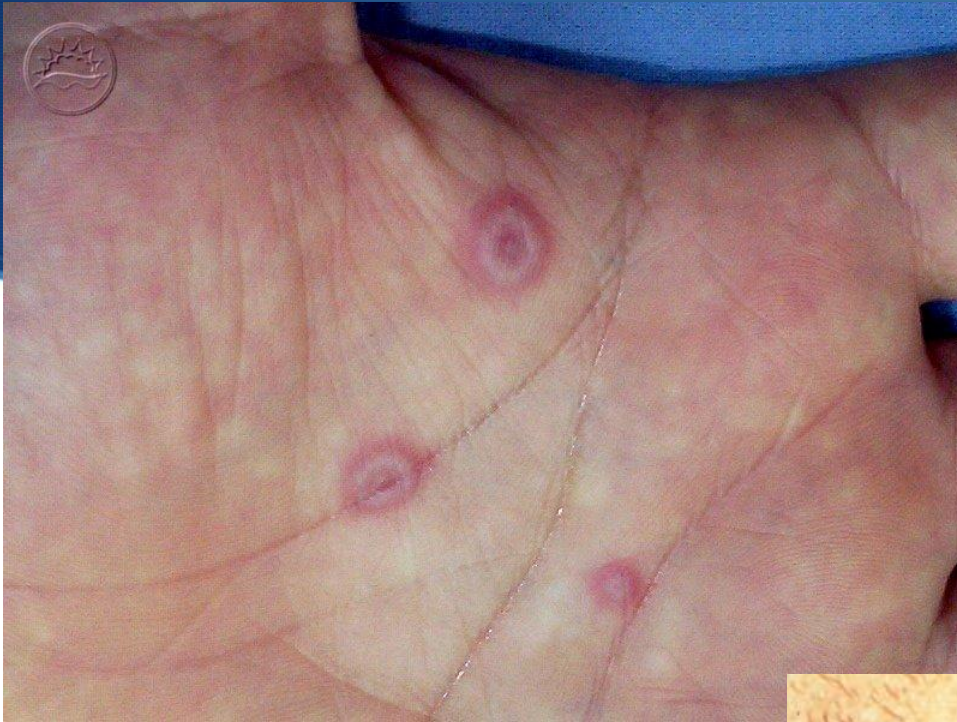Phenytoin

Carbamazepine

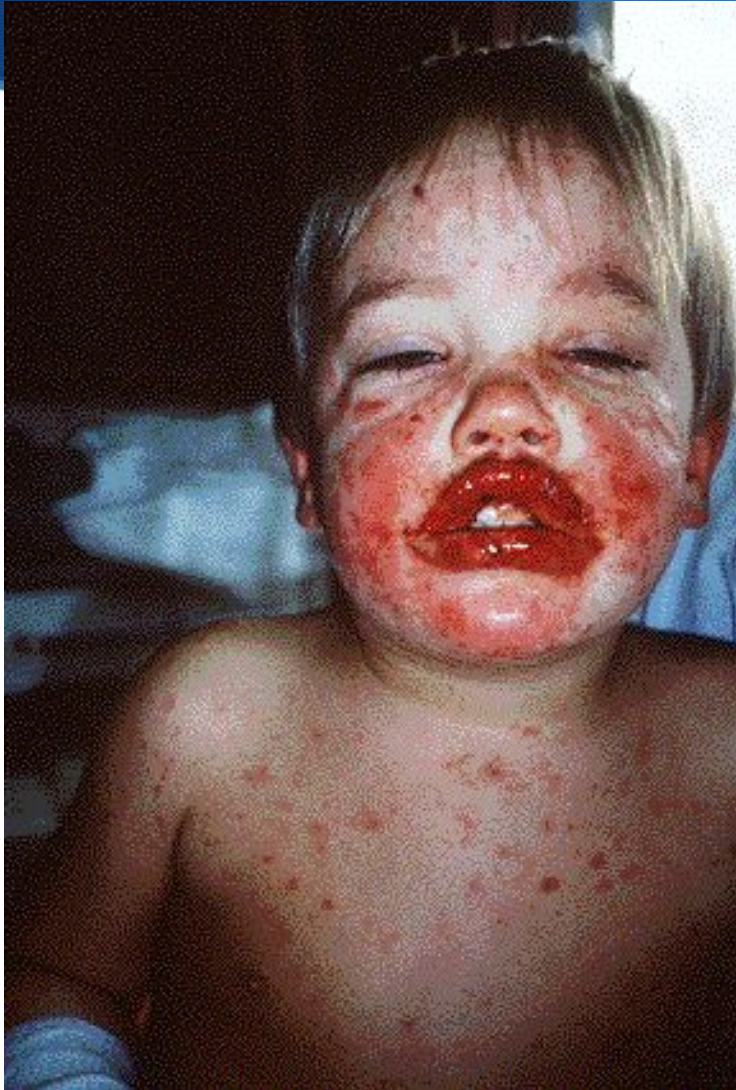Gold

Gentamycin





Erythema Multiforme



Medications include:

Barbiturates

Penicillins

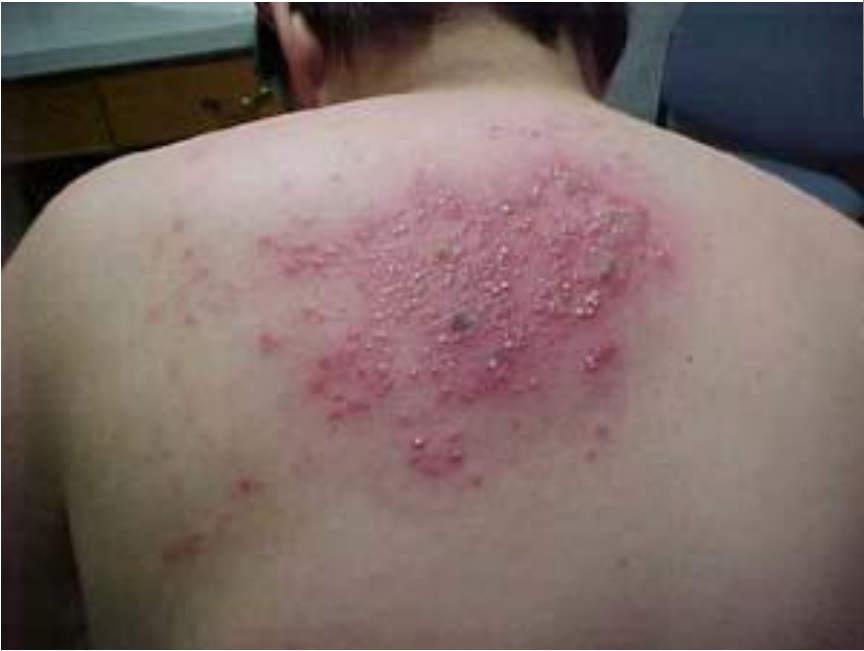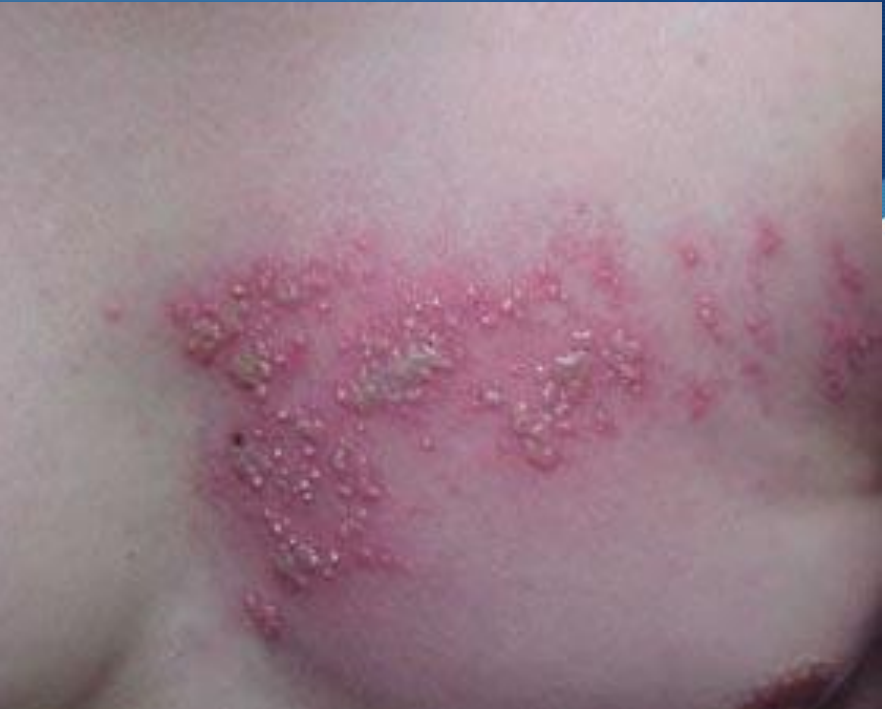Phenytoin

Sulfonamides

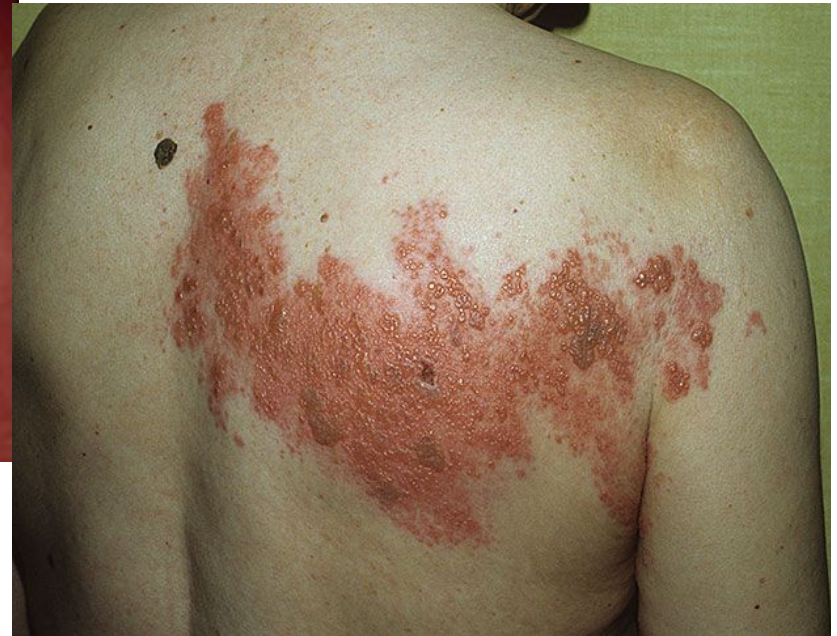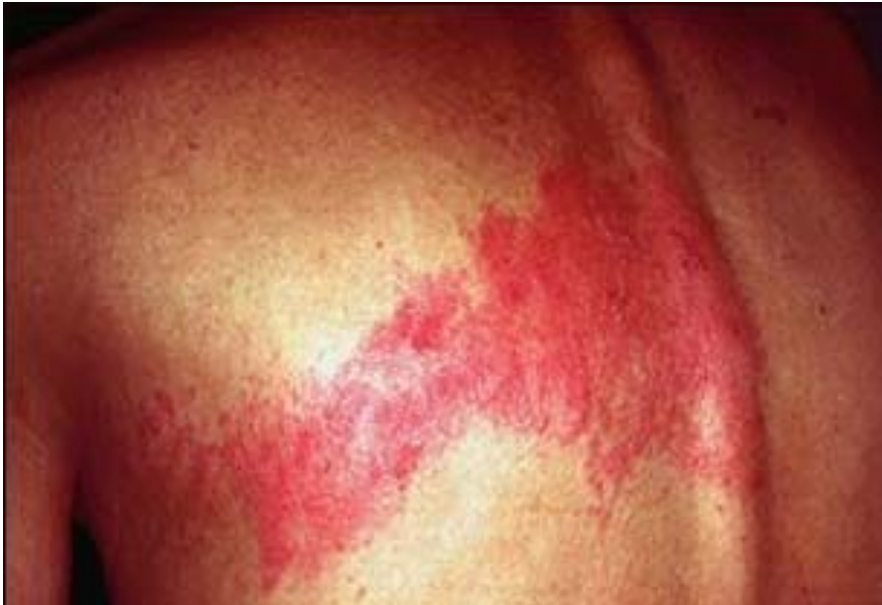Infections include:

Herpes simplex

Mycoplasma

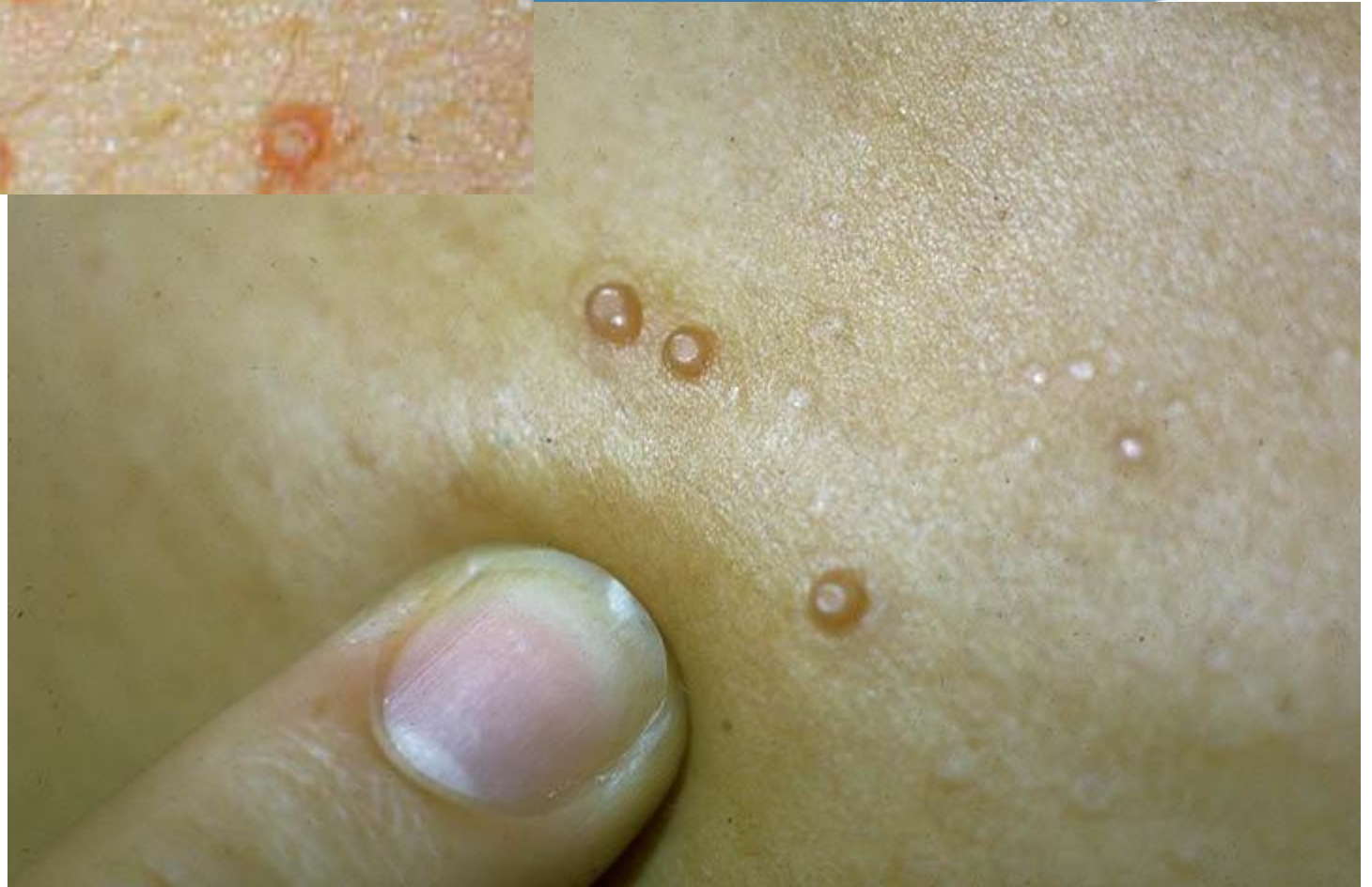
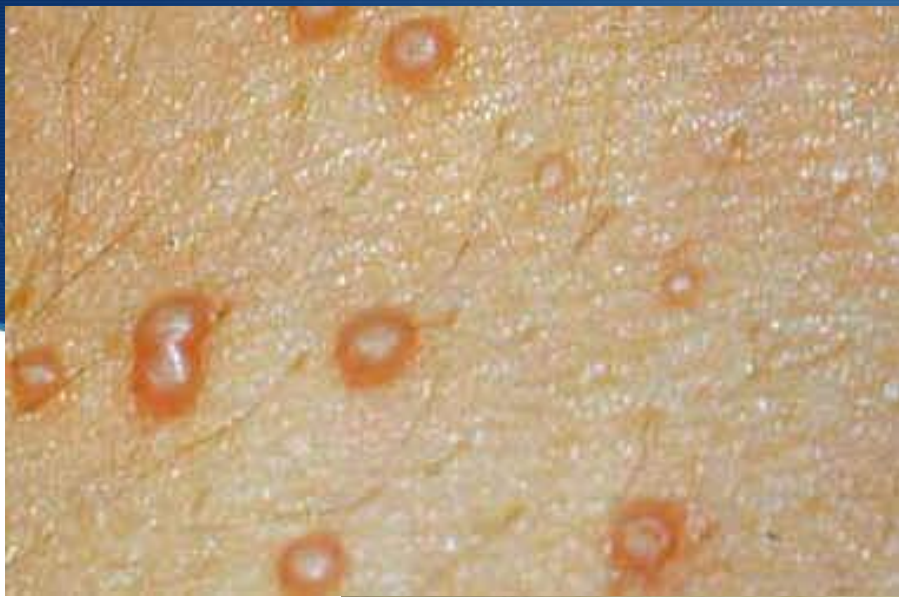
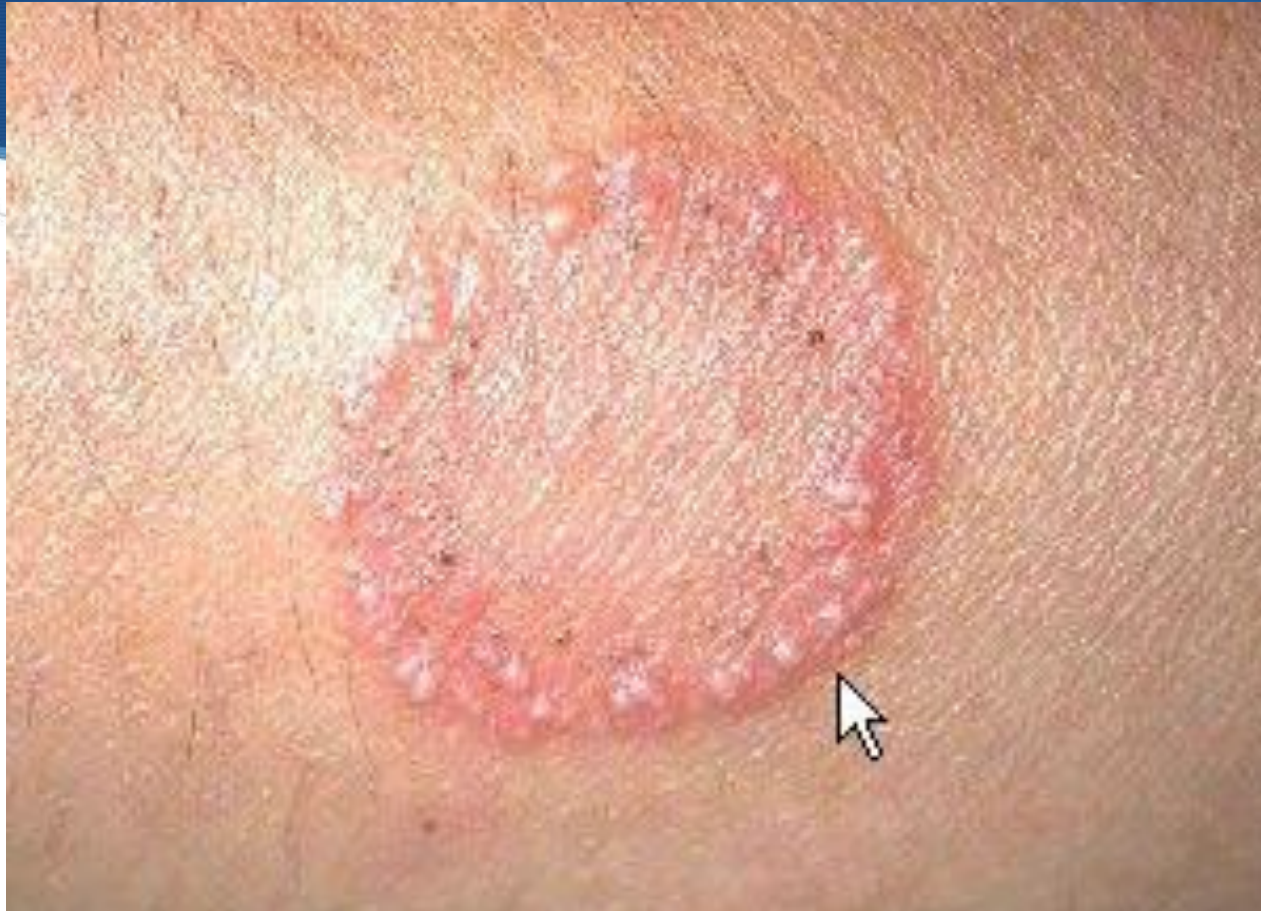Herpes Zoster



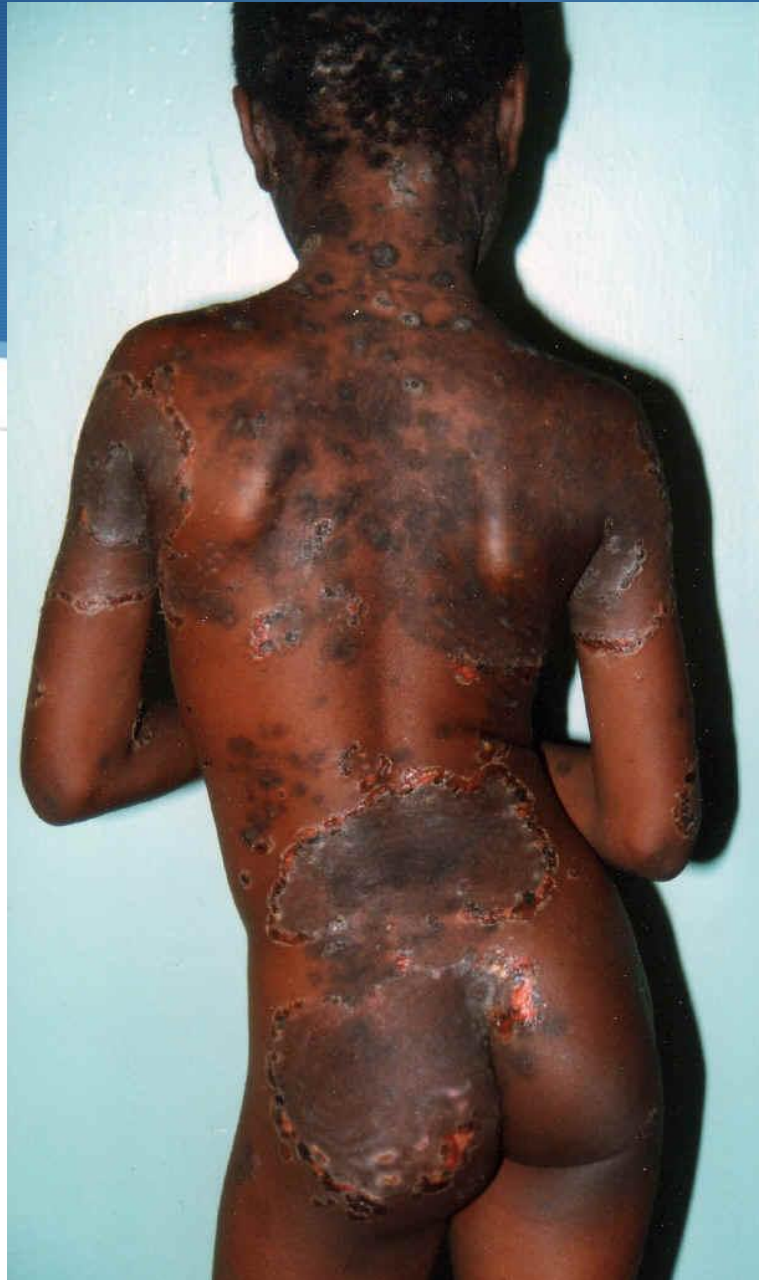Herpes Zoster

- 💧 Keep the rash covered, wash hands often
- 💧 Until your rash has developed crusts, avoid contact with
 - 💧 Pregnant women who have never had chickenpox or the varicella vaccine
 - 💧 Premature infants
 - 💧 Immunocompromised persons
- 💧 Acyclovir, valacyclovir, and famciclovir—will help shorten the length and severity of the illness. But to be effective, they must be started as soon as possible after the rash appears. **May prevent post-herpetic neuralgia.**
- 💧 CDC recommends vaccination in people 50 years old and older to prevent shingles. There is no maximum age for getting the shingles vaccine.

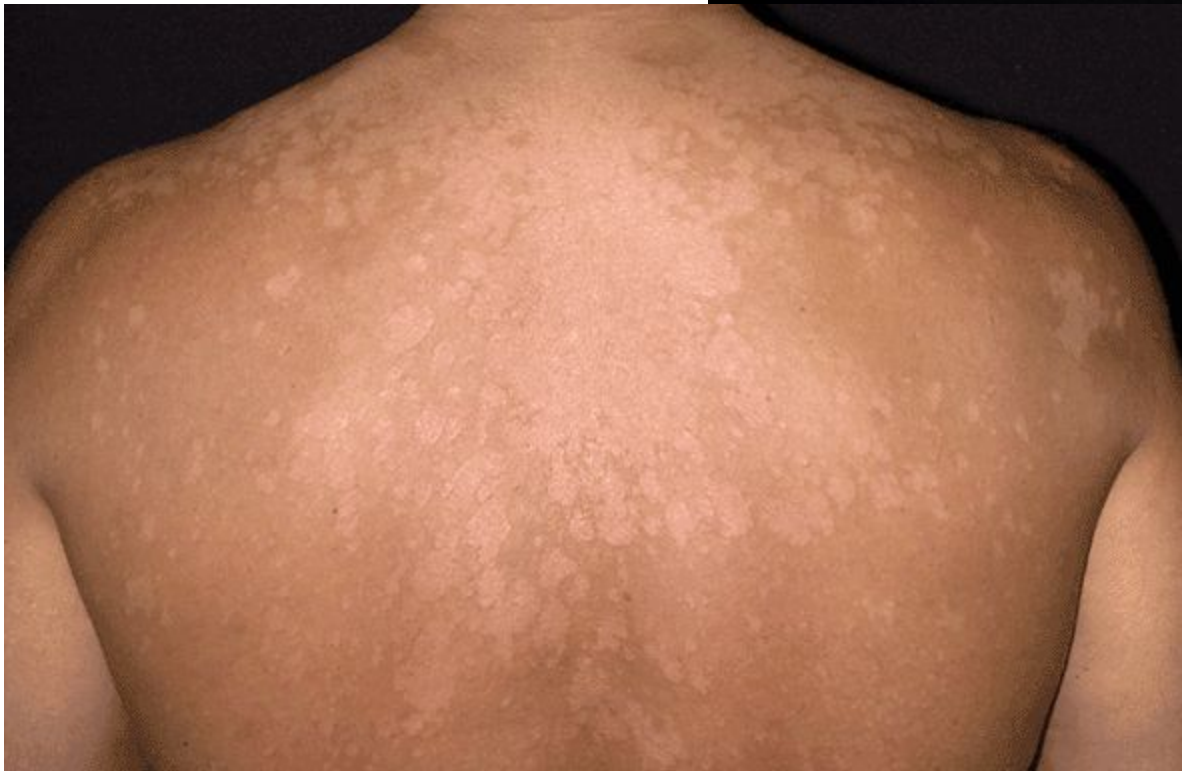
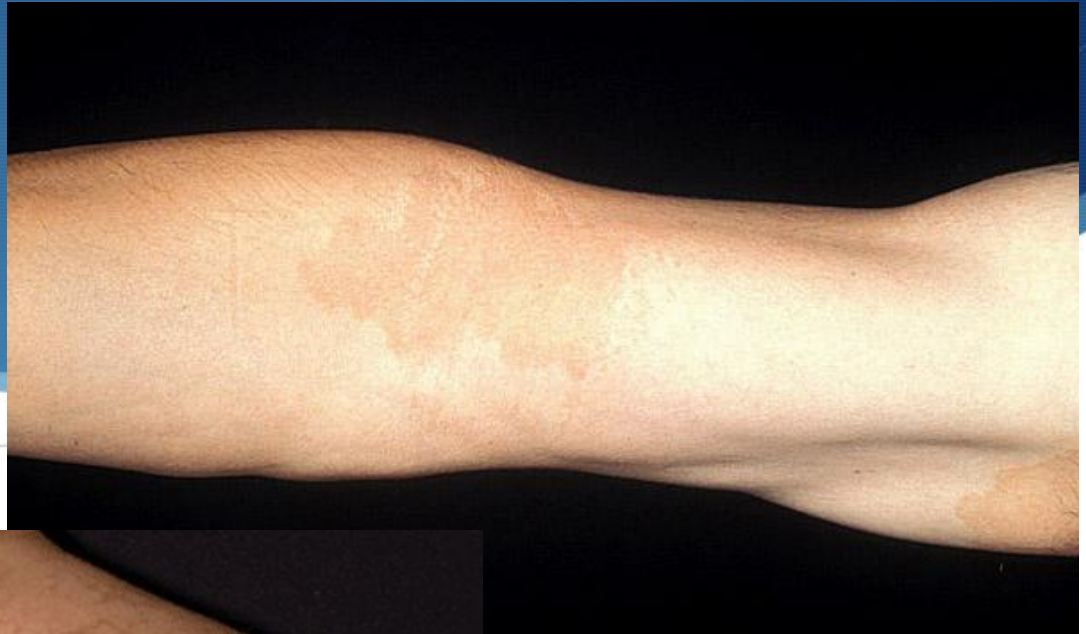


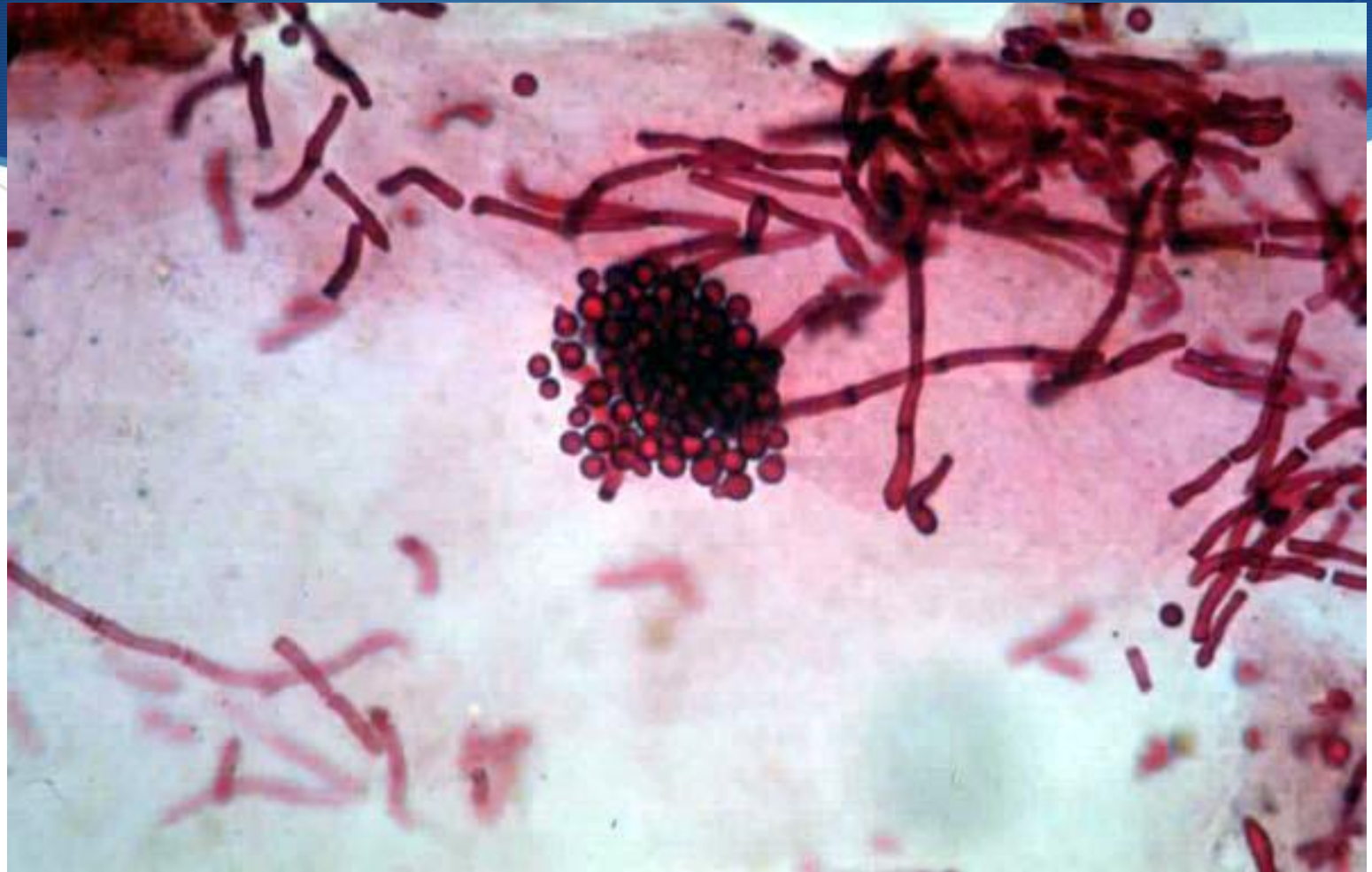Ringworm "Tinea"



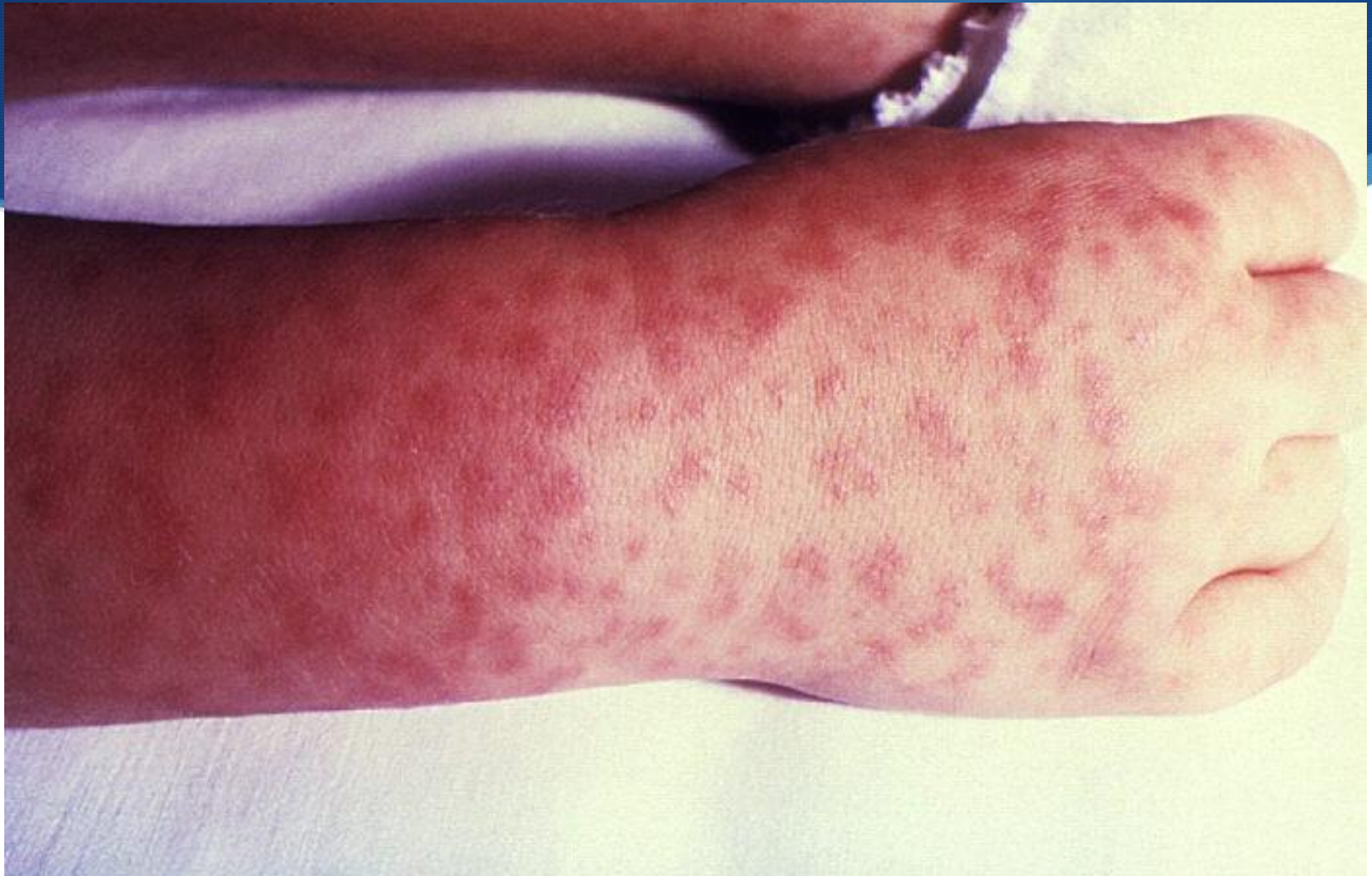Tinea
corporis



Tinea
versicolor



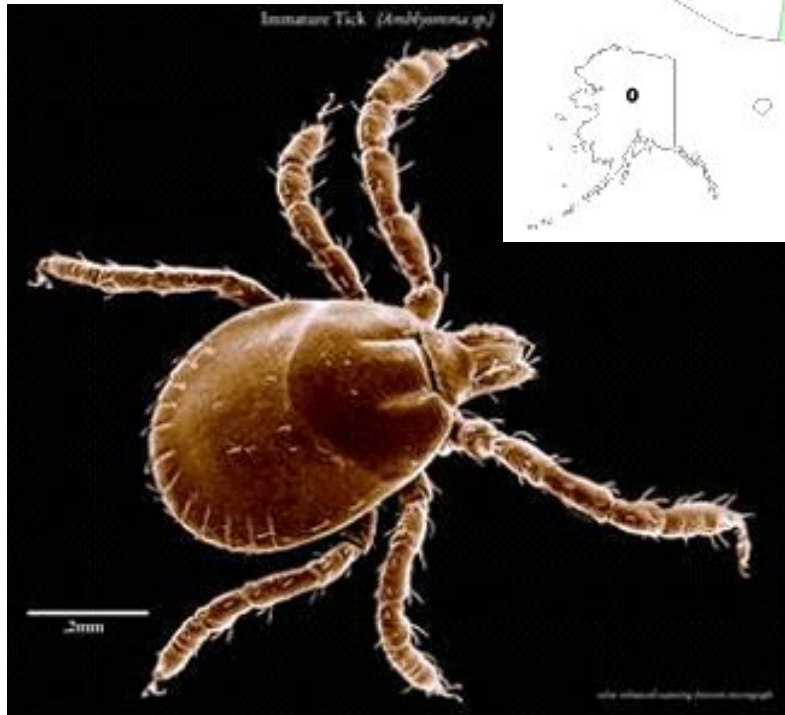
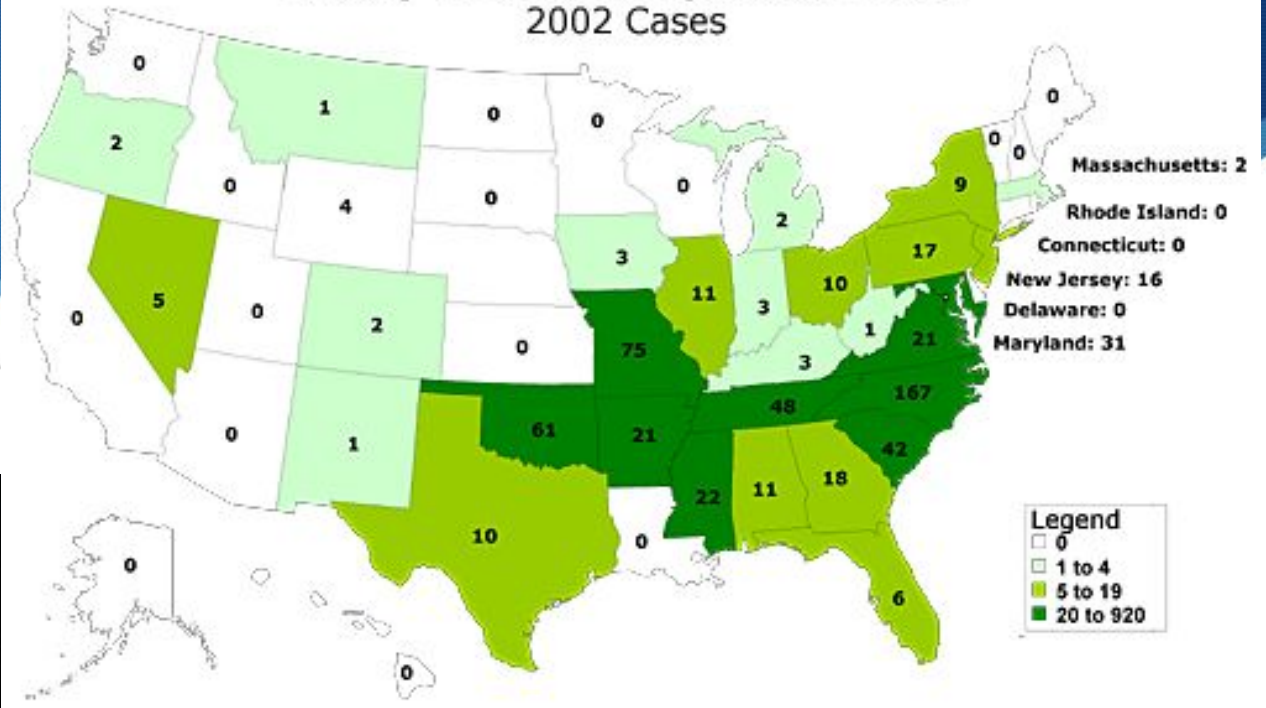


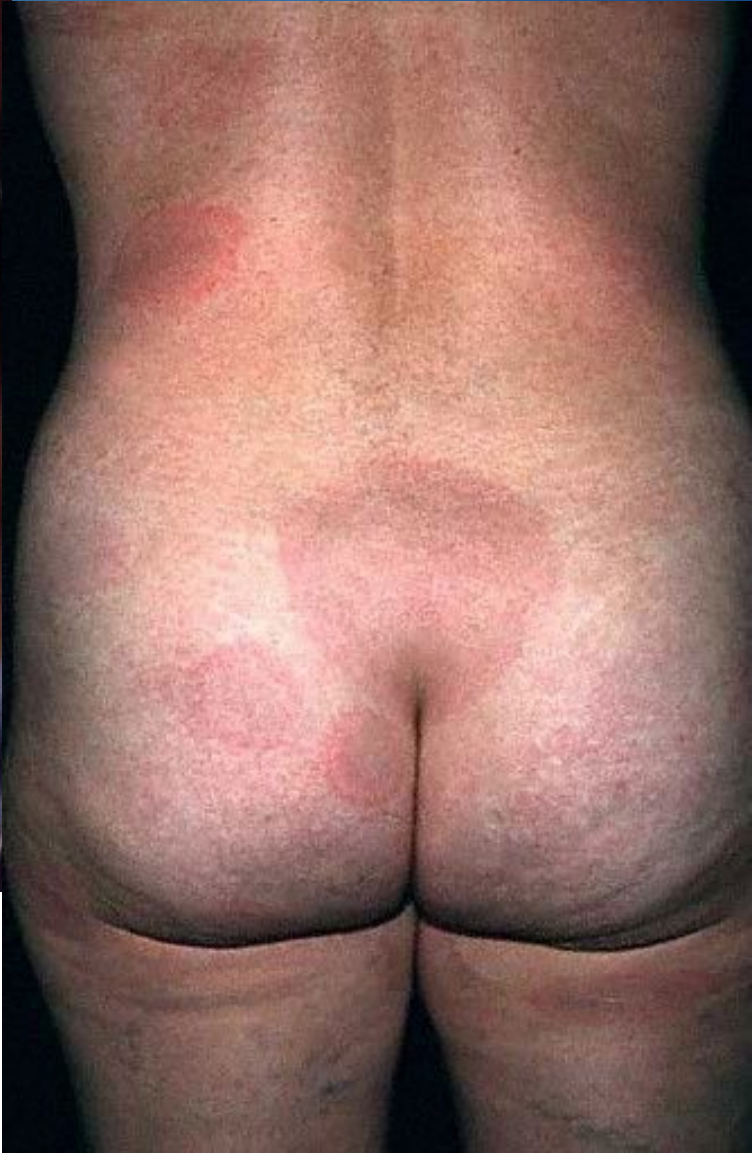
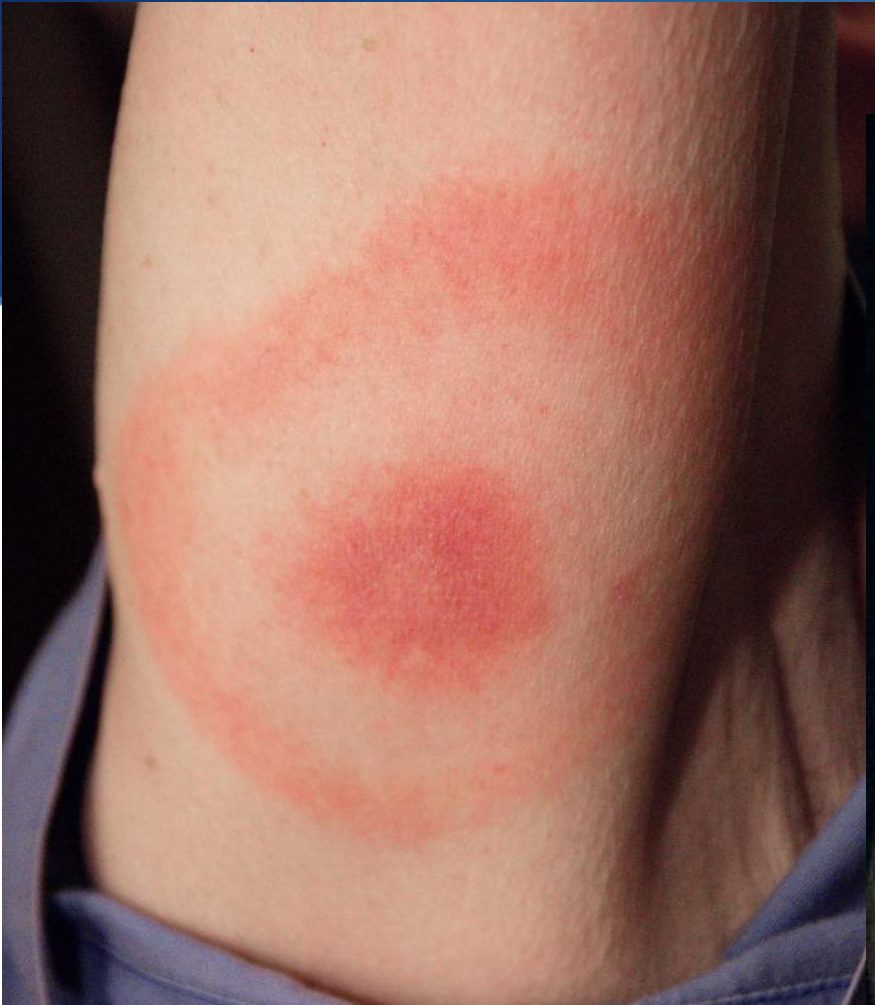
Which state?

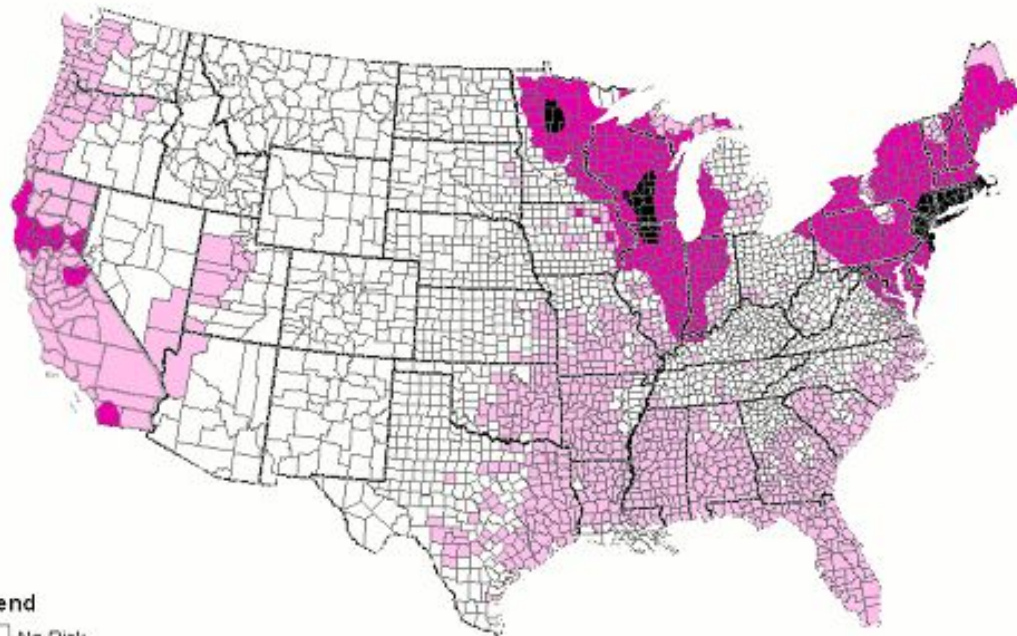
Rocky Mountain Spotted Fever

2002 Cases



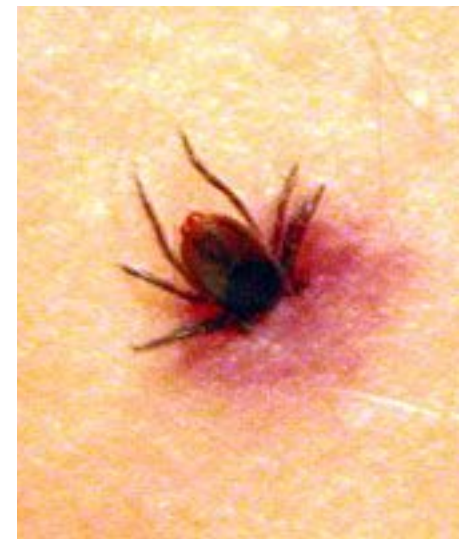

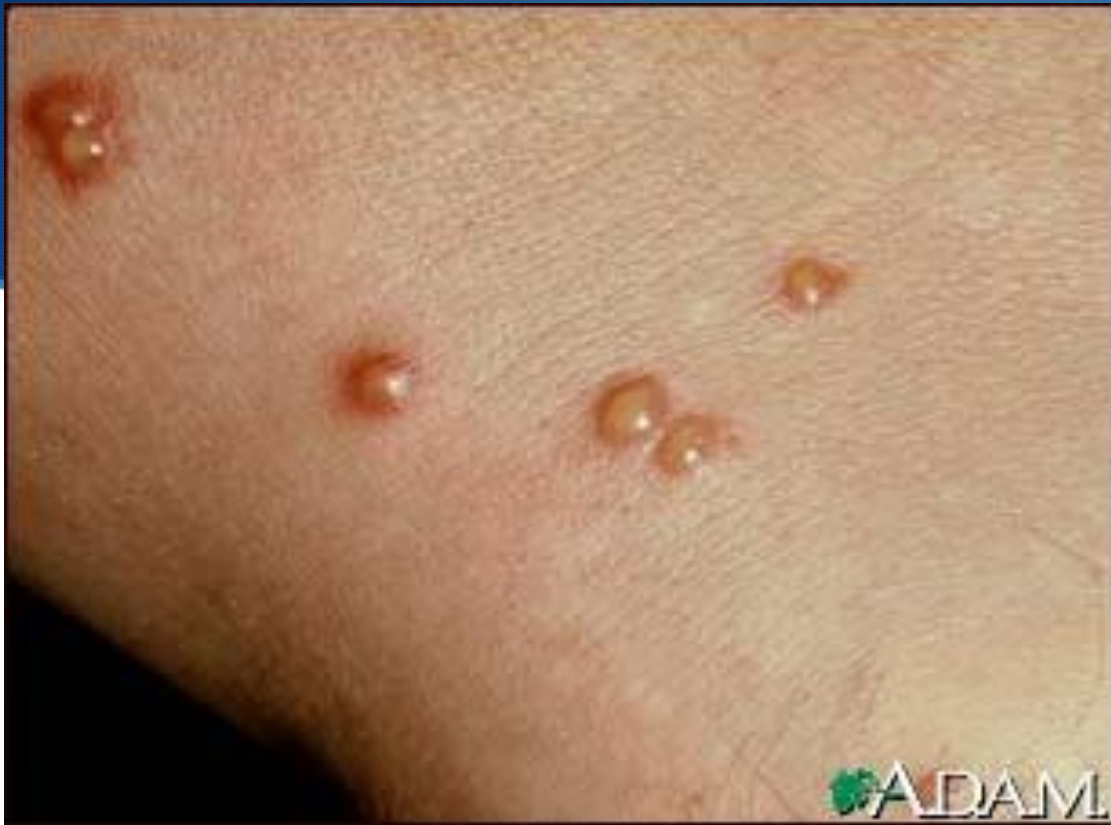Lyme Disease

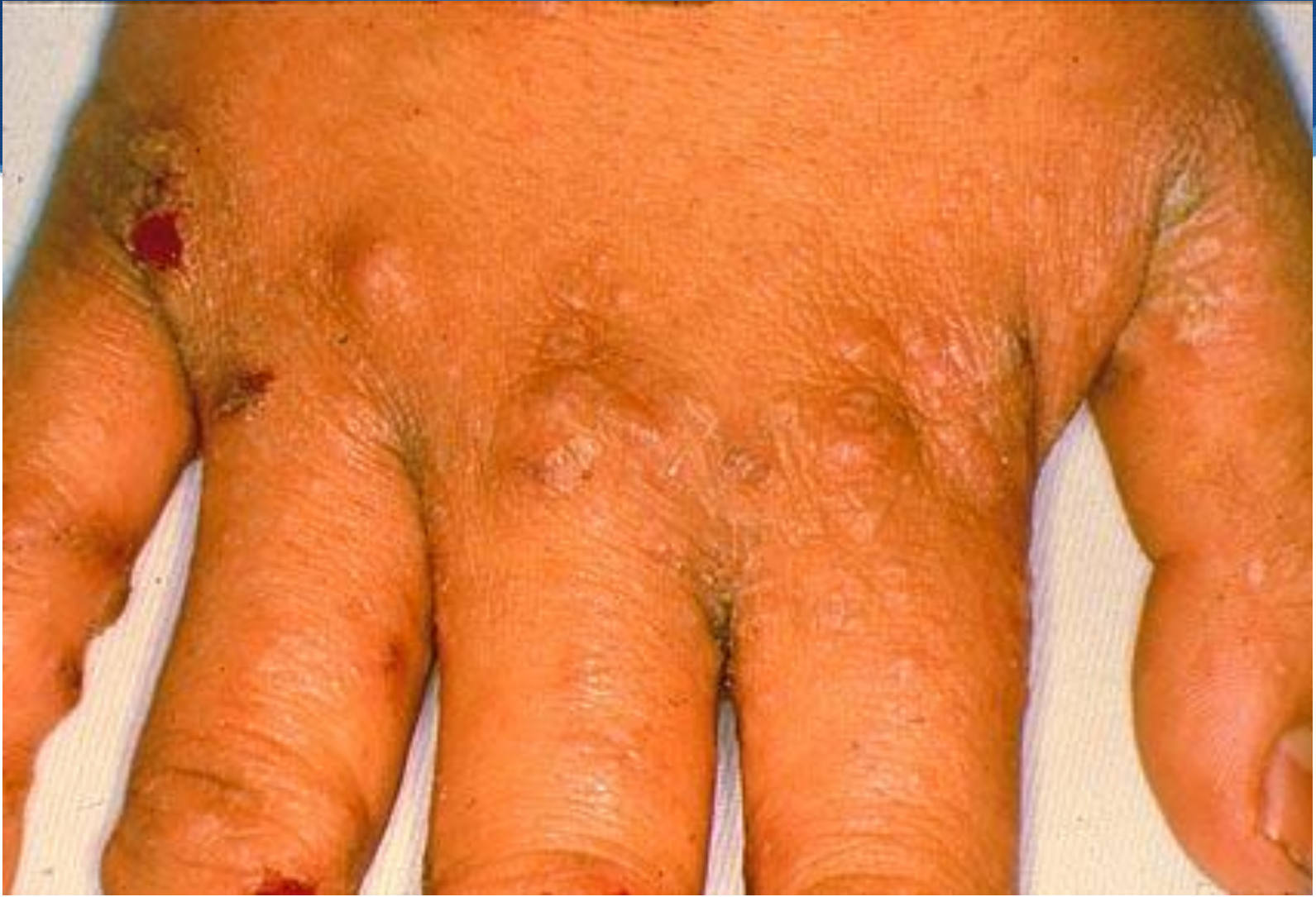

Legend

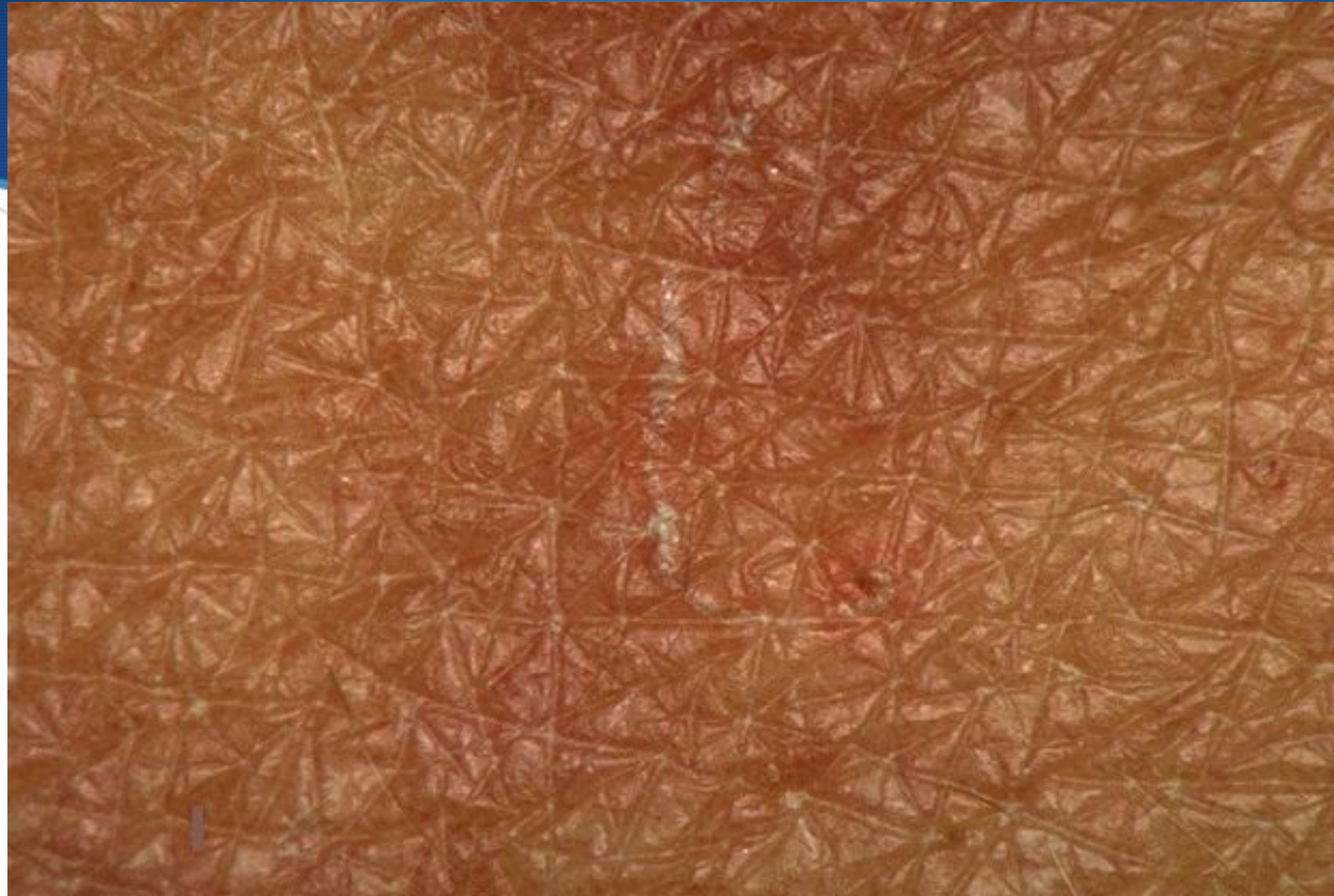- No Risk
- Low Risk
- Medium Risk
- High Risk

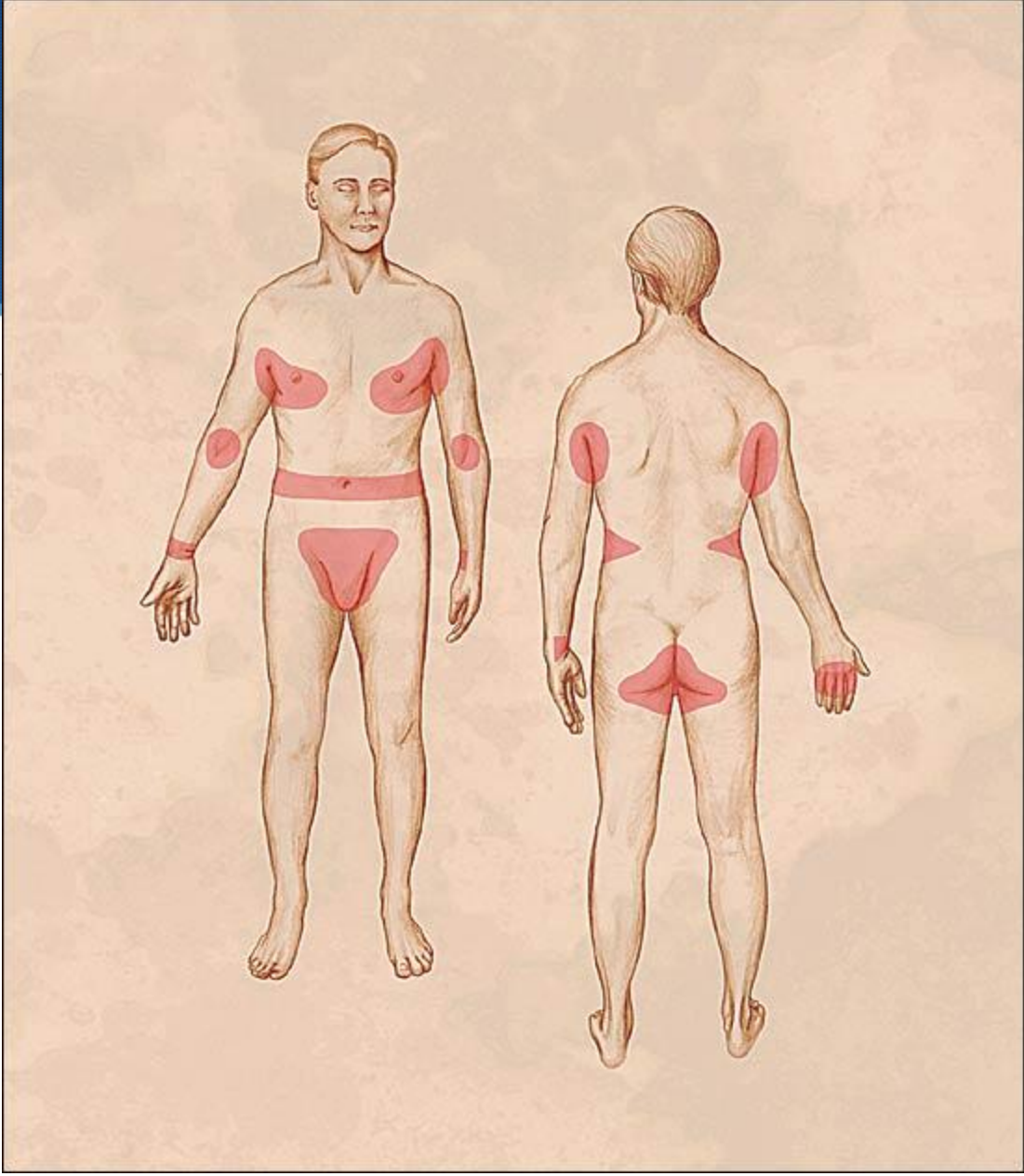




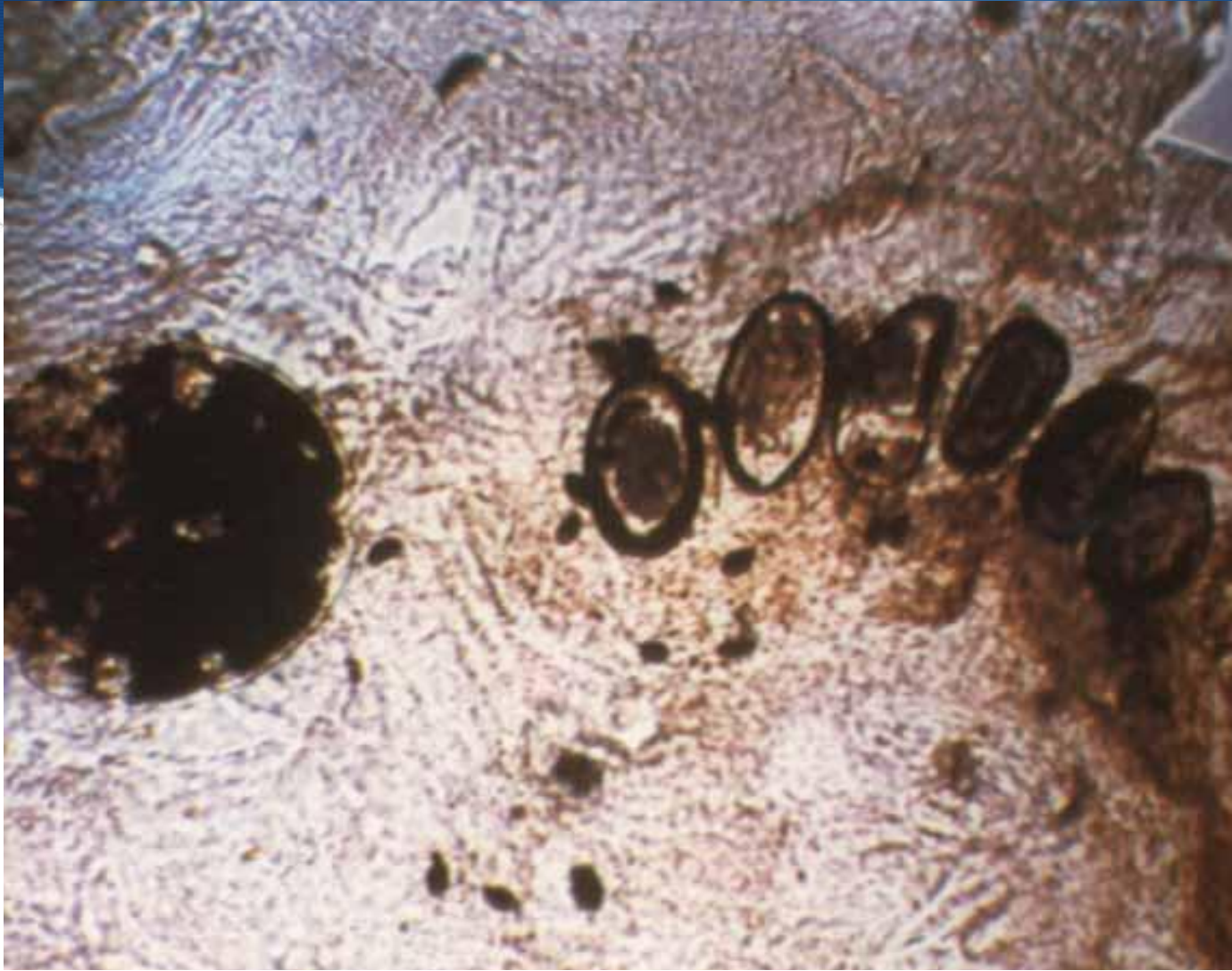

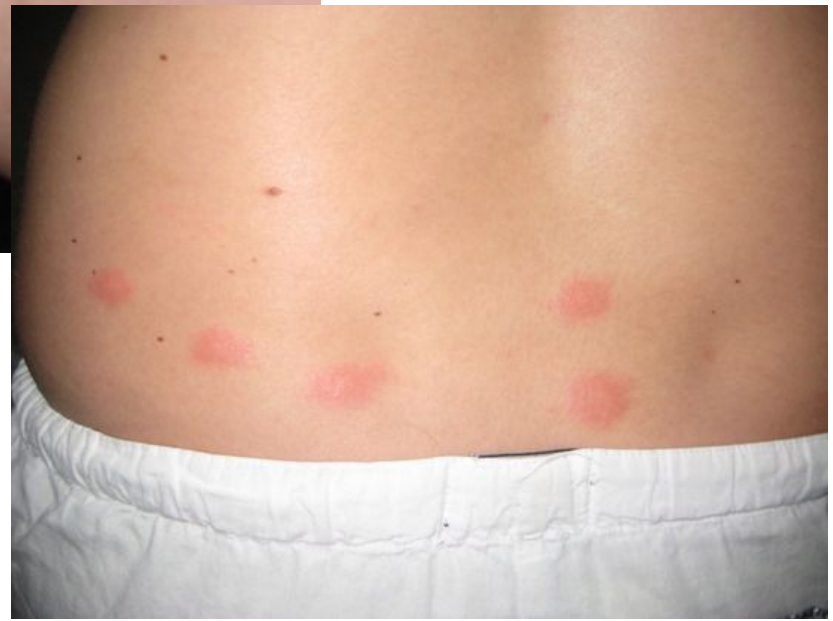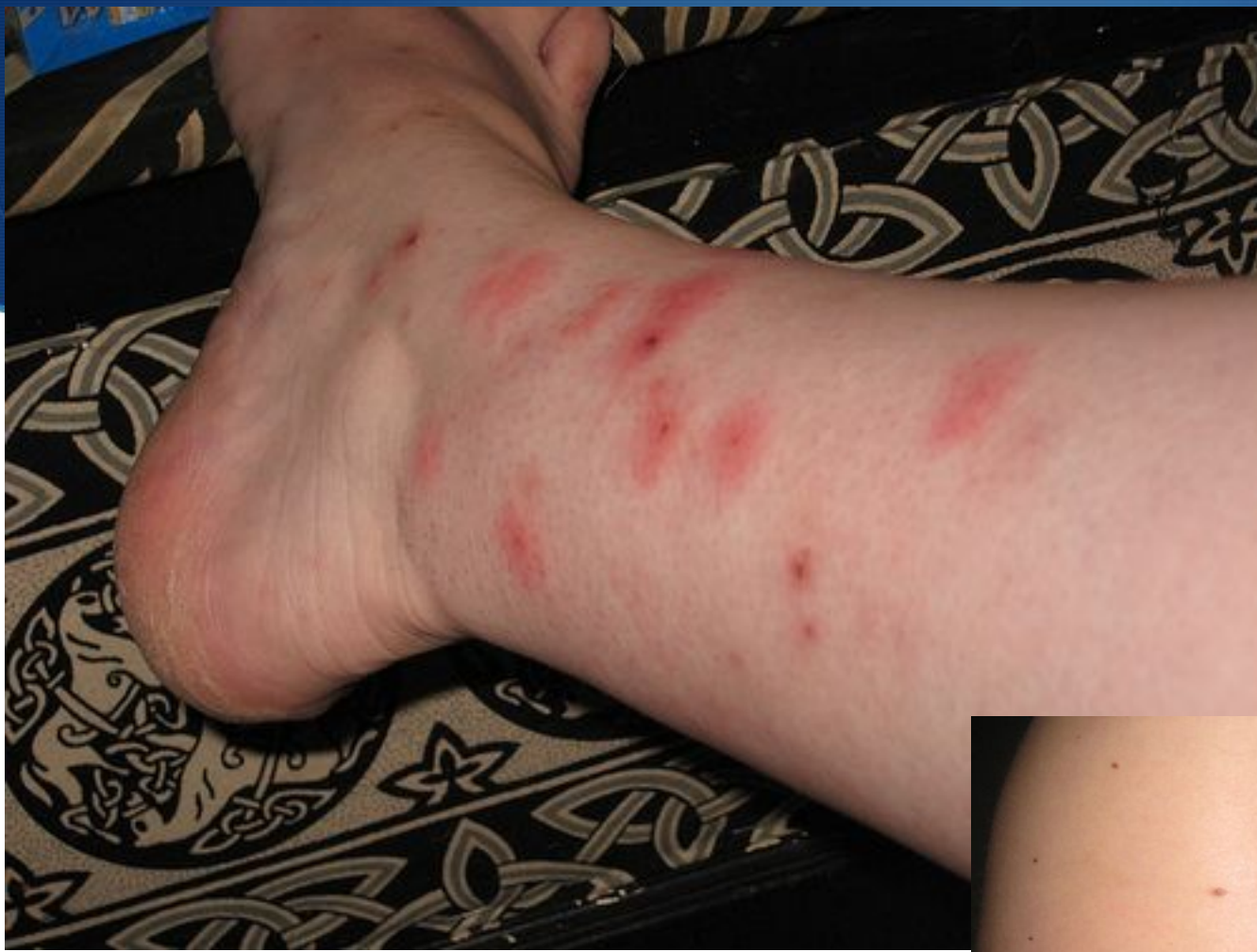Scabies





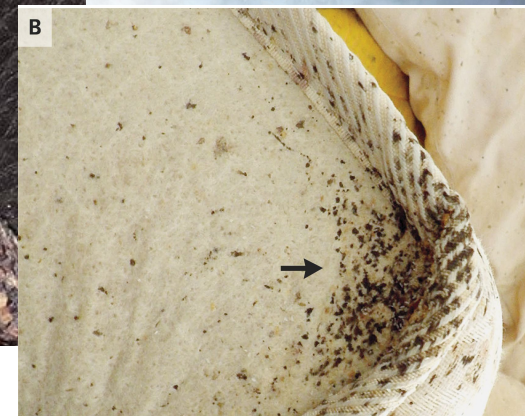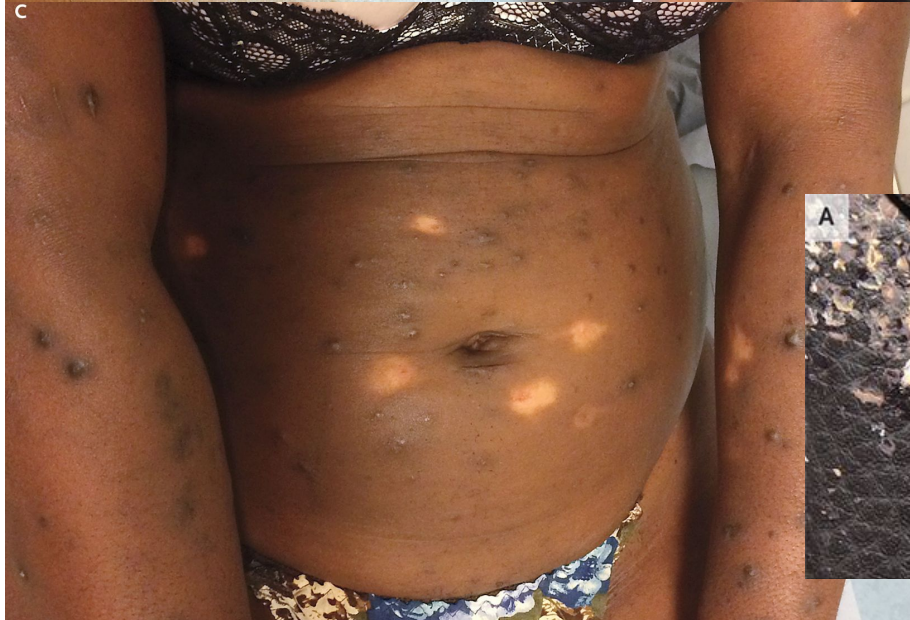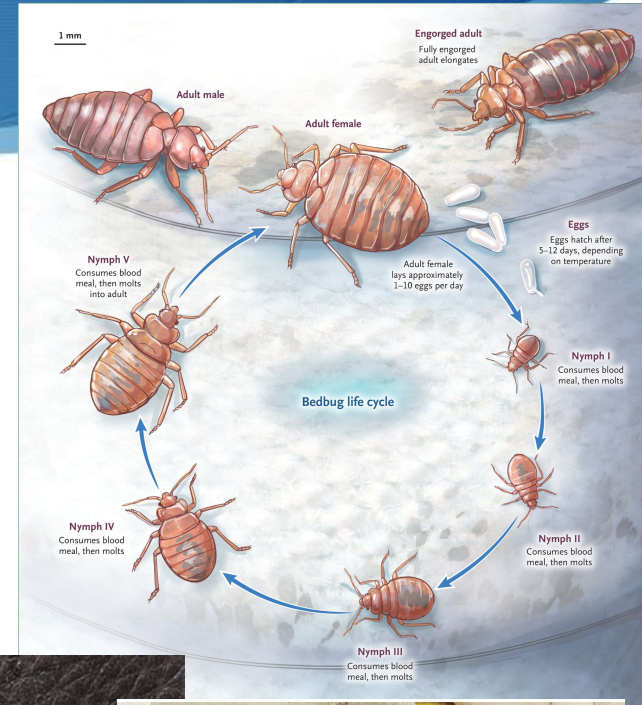
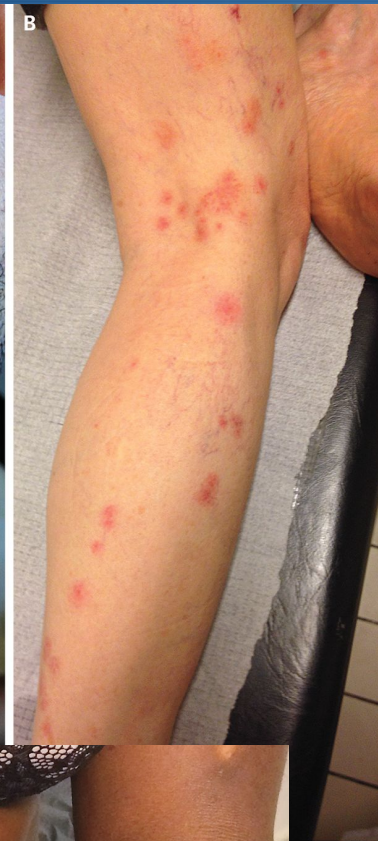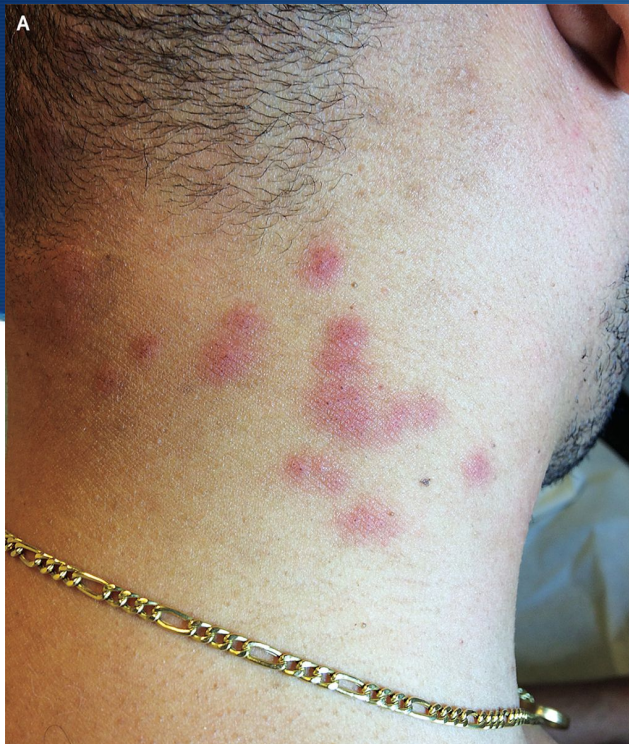© 2004 RENE CANNON





Bedbugs

Bedbugs on a sofa (Panel A)
and their fecal black spots (Panel B).



PERFECT SKIN

SUMMER 2013

YOUR ULTIMATE GUIDE TO FLAWLESS SKIN

BANISH CELLULITE

Three steps to a smoother you!

BOTOX

Fountain of youth or poison in your face?

NICE
&

NATURAL
Natural skincare remedies that work

True lines

Stopping wrinkles in your 30's

